

# HISTOLOGICAL STUDIES ON THE GONADS OF THE FOWL.

## I.—THE HISTOLOGICAL BASIS OF SEX REVERSAL.

BY HONOR B. FELL.

*(Paper from the Animal Breeding Research Department.)*

### I. Introduction.

IN a recent communication, Dr F. A. E. Crew described one case of complete sex reversal in the domestic fowl and seven others showing different stages in this process. The whole formed a consistent series which demonstrated the fact that an individual which had previously functioned as an active female producing eggs can on occasion undergo a complete sex transformation and come to function as a cock. Dr Crew handed to me the gonads of these fowls, and it is the purpose of this paper to describe in detail their histology and to discuss the bearing of the results of this histological examination upon the general question of sex reversal in the fowl.

I wish to express my gratitude to Dr Crew for his generosity in placing this valuable material at my disposal, and for much help and encouragement during the course of the work. I also wish to acknowledge my indebtedness to Dr L. T. Hogben for his invaluable criticism and advice.

### 2. Methods.

The eight birds comprising the series were kept under observation for eighteen months. After decapitation the gonad was removed immediately, and small pieces fixed by three or more of the following methods: in Flemming's solution without acetic acid; Regaud's bichromate formalin and Allen's modification of Bouin's fluid at 38° C.; by the method of Mann-Kopsch and Da Fano's metallic impregnation techniques. Flemming's solution, followed by a week's post-chroming and,

## Honor B. Fell

for nuclear and general histological study, Allen's technique were found to give the best results, although a few very good preparations were obtained by the impregnation methods. In the case of birds Nos. 2, 3, 4, the bulk of the gonad, after removal of small portions for detailed work, was fixed whole in Bouin's fluid and cut on a rotary microtome at a thickness of 7 to 8  $\mu$  for the purpose of studying the gross microscopic structure of the entire organ.

### 3. Description of Cases.

**No. 1.**—A Buff Orpington which, up to the age of 3½ years, had been an unremarkable hen: she had laid many eggs and raised many of her own offspring. In the autumn of 1920 she began to suffer from ovarian disease which became noticeable in January 1921. The head furnishings increased in size, and the feathers of the neck, saddle-hackle, and tail, as they were renewed, were seen to be cocky in structure. On February 1922 the behaviour, at first indifferent, had become actively male, and the bird could only be distinguished from a true cock by its slightly different stance and shorter legs. It was placed with a virginal Buff Orpington hen in a pen far removed from all other birds. In June the hen became broody and nine of her own eggs were placed under her. On 2nd July two chickens were hatched; the other eggs were clear.

In December the bird fell into an open drain and was drowned. Post-mortem examination showed that the fowl had been suffering from abdominal tuberculosis. Lying in the situation of the ovary was a rounded mass 7 × 4 cms. in size, with its purple surface marked with raised areas of yellow. Two testes were present, that on the left being incorporated in the dorsal aspect of the tumour mass. A thin oviduct could be identified on the left side and paired vasa deferentia were clearly discernible.

On sectioning, the structure of the gonads confirmed the conclusion that they were functional testes in a phase of reduced activity. The seminiferous tubules were precisely similar to those of the testis of a normal cock; they consisted of a well-defined basement membrane lined by seminal epithelium

## Histological Studies on the Gonads of the Fowl

showing every stage of spermatogenesis (fig. 1). They differed from the tubules of a very active testis in that they were smaller in size and showed fewer mitotic figures; ripe spermatozoa were usually present in the lumen but not in large numbers. The intertubular tissue, as in the case of the normal cock, occurred in small quantities, owing to the very small interstices between the tubules; it consisted of connective tissue only: no "luteal" cells were found. Both testes were invested by a well-developed fibrous tunica alluginea. Only one Wolffian body was sectioned. It resembled an epididymis rather than a parovarium, as a large distinct lumen was always seen in the ducts which were lined by columnar ciliated epithelium and usually contained groups of ripe spermatozoa.

The report of the Royal College of Physicians (Edinburgh) Laboratory stated that the ovarian tumour consisted of a mass of tubercular caseous material.

**No. 2.**—This bird was a Rhode Island Red, hatched in February 1921. The owner, when sending the bird, wrote: ". . . the sex of which I cannot tell. It is to all intents a pullet and looks almost as much like a cockerel." The head of the bird was as that of a pullet, there was no saddle-hackle, the neck-hackle contained some feathers distinctly intermediate in form, the tail was completely henny. Spurs were present on both legs, the one on the right measuring 1 cm., the one on the left 0.3 cm.

On dissection, the internal genitalia were found to consist: on the right of a testis measuring  $1.2 \times 0.5$  cms., on the left of an ovotestis, 4 cms.  $\times$  2 cms., with the spermatic portion nearer the mid-line of the body. Two oviducts were present, the left one 35.4 cms. in length by 1 cm. in diameter; the right one 20.2 cms.  $\times$  1 cm. Two vasa deferentia could be identified.

*Histology—Left Gonad.*—The general structure of the organ was that of an ovary consisting of a cortex and an inner zone of fibrous vascular cords, but the bulk of the cortex was composed of cords of epithelial cells similar to those described by Pearl and Boring in the gonads of certain abnormal hens. The testicular component was represented by immature and fully developed tubules occurring throughout the organ. The ovarian tissue consisted entirely of cystic follicles of various sizes (fig. 3); no

## Honor B. Fell

normal oöcytes being present. The cysts, which were occupied by a thin fluid and usually a few erythrocytes, projected above the surface in clusters, though smaller follicles were found among the epithelial cords. Hæmatopoietic foci, conspicuous owing to the large numbers of oxyphil granulocytes and granulocytoblasts present, were always found in the neighbourhood of the clusters and were probably assisting in the follicular involution. Many of the cysts were being invaded by epithelial cells—a phenomenon which will be described and discussed in dealing with the epithelial cords. “Luteal” cells were very abundant and occurred throughout the gonad as large conspicuous masses of cells with vacuolated cytoplasm and very definite cell walls. Their origin will be described later.

As we have already stated, the testis portion of the gonad was represented by numerous seminiferous tubules in various stages of growth (fig. 4). The mature tubules occurred chiefly in large groups situated in the more central parts. In none was spermatogenesis very active, and spermatozoa, when present, were few in number; spermatids were almost always found, but the majority of the germ cells were spermatocytes in different phases of synapsis: mitoses occurred in a few instances but were usually totally absent. A conspicuous fibro-cellular basement membrane bounded the tubules. In the more peripheral areas many of the tubules were in degeneration, the germinal epithelium having desquamated into the lumina, which became completely filled with an agglomeration of disintegrating cells; the intertubular tissue increasing in amount and becoming sclerotic and white fibrous tissue rupturing the basement membrane and invading the enclosed mass of seminal cells.

The histological features of this case suggested that apparently typical testicular tissue arises in what has been an ordinary cystic ovary in the following manner. It develops from a new set of sex cords proliferated from the germinal peritoneum covering the surface of the ovary. The ovotestis now being described proved particularly favourable material for a study of this phenomenon, and it is possible, therefore, to give a detailed account of the developmental process. If the

## Histological Studies on the Gonads of the Fowl

peritoneum of the ovotestis be compared with that of a normal ovary certain striking differences are observed, the most remarkable of which is the increased size of the cells in the case of the hermaphrodite gonad where they form a much deeper layer of columnar epithelium. Careful examination of well-fixed material shows that in the germinal peritoneum of the normal hen the nuclei contain polarised loops of chromatin. These loops were better defined in the peritoneum of the ovotestis and in some cells were double, the two halves being intimately twisted (fig. 6). There could be little doubt that these nuclei belonged to primary spermatocytes in the earlier meiotic stages, and a complete series could be traced between the condition of diffuse but polarised loops and characteristic contraction figures (pachytene), which latter also occurred in the peritoneum (fig. 7). The mitochondria were of the usual type found in the fowl, viz., short filaments. Besides the ordinary germinative cells of the peritoneum, two other forms occurred: (1) slender deeply staining cells with oblong nuclei; and (2) large spherical cells containing numerous fat globules. The nature of these cells was not clear. The peritoneum rested on a well-defined basement membrane which, however, was being broken down in various regions. The proximal ends of the epithelial cells sent out fine finger-like processes which penetrated the membrane; columns of cells then forced their way inwards into the subjacent tissue and thus formed the epithelial cords to which reference has been made. The cords were being proliferated at varying rates in different regions, and in places were separated by fairly wide intervals in which the basement membrane was still intact; while elsewhere they were developing side by side (fig. 5), and the basement membrane was reduced to fibrous strands displaced and wedged between the cords. In such actively growing areas the epithelium was several layers deep. The degree of differentiation of the cords also varied considerably and was greatest in the rapidly proliferating regions referred to above. Here spermatocytes formed a large proportion of the tissue from the first and were even comparatively numerous in the peritoneum. The sex cords developed into small tubules and these again into the mature tubules, although a

## Honor B. Fell

comparatively large number degenerated at every stage. Elsewhere, though growth was fairly active as evinced by numerous mitoses, differentiation was slight. In fig. 8 two typical cords are represented. They are seen to be composed of polyhedral cells with a large spherical or oval nucleus containing a plasmosome and cytoplasm showing numerous mitochondria. It is significant that in such undifferentiated regions there was almost always either a large quantity of deeply staining caseous substance between the cords or, if the latter were fairly widely separated from one another, dense ovarian stroma. This was not seen in areas of rapidly developing tubules. The caseous material was in process of absorption by the cells of the sex cords and appeared in the cytoplasm as irregular lumps and bars. Where this material was less compressed and therefore less deeply stained, it was seen to contain disintegrating nuclei, and represented the necrotic remains of the invaded ovarian tissue and also of degenerated sex cords. Spermatocytes were rare and typical pachytene stages were not found in the peritoneum from which such cords were being proliferated. Some of the sex cords were degenerating; the nuclei being hypertrophied to about twice their original size, the cytoplasm thin and granular, and the final stage of this process was represented by some of the amorphous material lying among the normal cords. Where these cords reached their ultimate development, they give rise to tubules which cytologically closely resembled those of the testis of a three months' chick, or of the resting testis of a sterile cock (fig. 2). The only appreciable difference was the almost total absence of convolution, which also characterised many of the more peripheral among the differentiated tubules. Pearl and Boring figure similar structures which they regard as being of mesonephric origin, but we are unable to coincide with their view for two reasons. Firstly, undoubted Wolffian bodies were sectioned in connection with the gonads of other members of the series and presented a very different histological appearance (fig. 21); secondly, because the cords from which the tubules were derived, originated from peritoneal proliferations in precisely the same way as do the typical differentiated tubules. A large area of undifferentiated tubules were found

## Histological Studies on the Gonads of the Fowl

at the anterior end of the ovotestis, which were densely packed together, while the intertubular tissue was composed largely of distorted sex cords undergoing pressure atrophy. The tubules were branched and showed few or no convolutions; the cytoplasm of the germinal epithelium was syncytial and had a radiating fibrillar appearance. In certain instances it completely filled the lumen, in others there was a central cavity; the oval nuclei were ranged in a single layer within the basement membrane. Some of the more central tubules were degenerating, the cytoplasm becoming granular and the nuclei shrunken and scattered throughout the syncytial cytoplasm. In other cases a layer of normal epithelium surrounded a central mass of cell debris. Towards the periphery the tubules gradually merged into undifferentiated sex cords of the usual type. Proliferation from the peritoneum had ceased and a fibrous tunica albuginea had been laid down. Mitotic figures were numerous both in the cords and in the outer tubules. Groups of "luteal" cells were present.

In view of the histological structure of the gonads of other fowls of this series, it was very important to trace the actual differentiation of the sex cords as opposed to their growth. It would have been extremely difficult to interpret the subsequent histological pictures had not the homology of the differentiated and undifferentiated cords been established by (a) their common origin from the ovarian peritoneum; and (b) the presence of a finely graded series showing a steadily diminishing number of spermatocytes, which thus linked the two extremes of a sex cord composed largely of typical spermatocytes and one consisting entirely of undifferentiated epithelial cells. Differentiation is probably correlated with the favourableness of the internal environment. It has been pointed out that the large mature tubules occurred in the more central parts of the cystic ovary where ovarian stroma is always loose, while the undifferentiated cords were found either in very dense tissue or else interspersed with streaks of fluid which probably represented the remains of such tissue. In resistant regions there was at first a huge mortality among the invading cells. One portion of the gonad showed this very plainly. Few definite cords had been formed and the invading epithelial

## Honor B. Fell

cells were in diffuse syncytia which took advantage of the intercellular crevices of the stroma. Some of the clefts in the stroma were lined on one side by a layer of these cells. The majority of both stroma and epithelial cells were degenerating, and were sometimes so necrotic as to be almost indistinguishable. The overlying peritoneum was greatly thickened, the basement membrane was being ruptured, and small proliferations were growing inwards to invade the devastated area with a fresh set of cords. The necrotic tissue already present would probably have been reduced to the densely staining amorphous material we have described. Several successive proliferations of sex cords seem to have taken place throughout the ovotestis. In one region which was occupied by healthy undifferentiated cords and streaks of caseous material, the connective tissue cells underlying the peritoneum had become arranged with their long axes parallel with the surface preparatory to forming a tunica alluginea. The germinal epithelium, however, was greatly thickened, the cells had penetrated the basement membrane in the usual manner, and in places invaginations were pushing downwards into the developing albuginea the cells of which were compressed and displaced at these points.

It has already been stated that the cystic follicles might become invaded by epithelial tissue, and numerous instances of this were to be seen. The first stage in the process was the appearance of a knob of typical sex cord tissue projecting into the cavity of the cyst. In some cysts these knobs were seen to contain spermatocytes in the pachytene stage. Ultimately the cavity became completely filled with epithelial cells in various stages of development, and sometimes large cysts occurred containing considerable numbers of scattered seminal cells in every stage of spermatogenesis. These cells lie amongst the fluid material and erythrocytes which constituted the original contents of the cyst. In most cases at any rate the cells disintegrated owing, probably, to lack of nutriment. In the smaller cysts the seminal cells fared better, and became arranged around the wall in a regular epithelium in active spermatogenesis.

It has recently been shown by Nonidez that in the embryonic



## Histological Studies on the Gonads of the Fowl

testis of the fowl, particularly in the case of hen-feathered birds in which "luteal" cells are normally present in the adult, the early tubules may be transformed into groups of the so-called "luteal" cells, instead of giving rise to functional tubules in the ordinary way. In view of these results, it is interesting to record that in this ovotestis now being described the large areas of "luteal" cells, previously referred to were also derived from the sex cords. Usually several adjacent cords underwent the same process, thus giving rise to the very large groups that have been described. The changes which the cells of the cords underwent were most easily followed in material fixed in Allen's fluid and stained with iron hæmatoxylin. In such preparations the cytoplasm was seen to become less dense and vacuoles began to appear (fig. 9). These steadily increased in number, the nucleus began to shrink and finally assumed a crenated appearance owing, possibly, to the pressure of the substance accumulating in the cytoplasmic vacuoles (fig. 10). The cells finally presented that startlingly clear appearance so characteristic of the so-called "luteal" tissue when preserved in picro-acetic fixatives (fig. 11). Nonidez suggests that the formation of these cells is a process of fatty degeneration—a view which is supported by the fact that in the ovotestis the groups of luteal cells were always far more numerous in areas in which the cords were completely undifferentiated and appeared to be competing with difficulty against the ovarian stroma.

*Right Gonad.*—The small right gonad (fig. 12) was composed of three types of tissue: (1) Large functional seminiferous tubules; (2) atrophic tubules; (3) undifferentiated sex cords and large groups of "luteal" cells. The mature tubules contributed about one-third of the organ and were typical in structure. A few fully formed spermatozoa were present in most but, as in the left gonad, spermatogenesis apparently had not been very active and mitotic figures were uncommon. As in the normal functioning testis, the tubules were closely packed together and the small interstices were filled with loose connective tissue. The atrophic tubules formed large groups lying between the fully developed tubules and the sex cord region. Their structure was similar to that of the resting

## Honor B. Fell

tubules of the left gonad but they were more degenerate. The syncytial cytoplasm was scanty and showed the fibrillar appearance in a marked degree, while mitotic figures could not be found. One of these tubules appeared to have been regenerating and contained spermatocytes in the pachytene phase. The lumina rarely showed a central cavity. The intertubular tissue was dense and interstitial groups of "luteal" cells were common. The sex cord region consisted entirely of the undifferentiated cords described in the left gonad. The invaded tissue appeared to be chiefly plain muscle which, however, was only recognisable near the periphery owing to the necrotic condition of the tissue in the centre. Enormous quantities of deeply staining amorphous material lay among the cords, and was especially abundant in the central parts. Many of the cords were degenerating and showed great nuclear hypertrophy and thin granular cytoplasm. Large groups of "luteal" cells were present among the cords. The entire organ was enveloped by much muscular and fibrous tissue which, in the region of the functional tubules, formed a regular albuginea with numerous blood vessels.

Attached to one end of the gonad was a group of small ducts lined by rather shallow columnar ciliated epithelium which evidently represented a Wolffian body. The ducts were embedded in a stroma of connective tissue. Lying nearer the gonad were a number of anastomosing vessels lined by cubical epithelium probably representing a rete.

**No. 3.**—A Rhode Island Red which was regarded by its owners as a henny-feathered cock. It crowed but very exceptionally and only in answer to another. Its behaviour was peculiar—it played the part of a male toward other birds but never was it observed to tread. The feathering generally was henny, but many of the neck-hackle feathers were intermediate in structure though much more henny than cocky. The comb measured at its highest point 4 cms., the wattles were 5 cms. long. The left spur was 2.5 cms. long, the right one was represented by a mere button measuring 3 mm.

On dissection, the internal genitalia were found to consist of a small testis on the right, and on the left of an ovotestis irregular in outline, with pediculated ovarian portions con-

## Histological Studies on the Gonads of the Fowl

taining convoluted atretic follicles. On the right side there was a vas deferens and on the left an oviduct 10 cms. in length and about 3 mm. in diameter near its termination.

*Histology—Left Gonad.*—The bulk of the gonad was composed of functional testicular tissue and the ovarian elements were confined to the extreme periphery and the interlobular clefts (fig. 13). The ovarian tissue was represented by: (1) numerous oöcytes of various sizes; (2) cystic follicles containing a thin, jelly-like material; (3) numerous large discharged or atretic follicles, easily recognisable with the naked eye, occupied by vacuolated cells many of which contained yellow pigment. In the intertubular clefts the ovarian tissue was distinct from the testis portion with which it was connected by fibrous vascular cords. Groups of atrophic tubules similar in structure to the resting tubules in the ovotestis of No. 2 were, however, occasionally seen in the stroma. Elsewhere the ovarian and testicular constituents occurred together as a solid block of tissue. The oöcytes were typical and contained a large vesicular nucleus with chromosomes in the late diplotene (chiasma) stage. Beneath the nucleus Da Fano preparations showed the large aggregate of filamentous mitochondria and crescentic Golgi rods characteristic of the oöcytes of the fowl. All the largest and many of the smaller oöcytes were in degeneration, the outline having become irregular, the nucleus shrunken and its chromosomes broken down into a heap of chromatin granules, the mitochondrial area becoming very dense and concentrated, and large vacuoles beginning to appear in the cytoplasm. The membrana granulosa had thinned out to a mere line, and the follicle was finally reduced to one of the cysts to which reference has been made. In some cases the oöcytes were undergoing the usual form of atresia, resorption by the proliferating granulosa cells. The so-called "luteal" cells were plentiful both as the usual small islets in the thecæ externæ of the follicles and also in larger masses unassociated with a follicle. Islets could also be found among mature testis tubules. Hæmatopoietic foci showing granulocytoblasts in different stages of formation occurred in various regions.

The spermatic tissue was best developed in the central portion of the gonad, where it was composed of large tubules

## Honor B. Fell

in active spermatogenesis. These formed a much greater proportion of the organ than was the case in the ovotestis of No. 2, in which the fibro-cellular cords of the hilar region though reduced in number and size were still distinct and not, as in the present instance, completely obliterated by mature testicular tissue. The tubules, which were separated by comparatively wide spaces occupied by loose areolar tissue, showed every phase of sperm formation, and spermatozoa were almost invariably present. Towards the periphery of the gonad, the tubules became steadily less differentiated in character. At first, though still in active spermatogenesis, they were seen to be of smaller cross-section, more closely packed together, and embedded in a denser fibrous stroma. Next, spermatozoa and spermatids were no longer present, and the seminal epithelium consisted chiefly of spermatogonia and primary spermatocytes, most of which were in the contraction pachytene phase. Finally, for some distance beneath the surface, the tissue consisted of cords of cells among which the oöcytes were scattered. The cords as usual were composed of oblong or polyhedral cells containing a large spherical nucleus, occupied by a few small granules of chromatin and a plasmosome. Mitoses were numerous and synaptic figures, though most frequent in the more central portions of the cords, occurred throughout their length. Da Fano preparations showed that the mitochondria were of the ordinary filamentous type, and the Golgi apparatus like that of the germinal epithelium of the tubules, appeared to consist of a split horseshoe-shaped rod enclosing the archoplasm (fig. 14). Even at the extreme periphery of the ovotestis functional tubules were occasionally found and sometimes occurred as groups of large tubules situated in a protuberance from the surface of the gonad. The fibrous capsule enclosing the protuberance usually contained heaps of the so-called "luteal" pigment, and it seems probable that they represented an old discharged or atretic follicle. In those parts of the gonad which were occupied by the sex cords, the peritoneal epithelium was seen to consist of enlarged cells which formed a layer of deep columnar epithelium sharply limited from the subjacent tissue by a basement membrane. Mitotic figures were common, and

## Histological Studies on the Gonads of the Fowl

here and there typical synaptic figures were seen. At intervals the basement membrane was ruptured and the peritoneal cells were in continuity with one of the sex cords. No active regions of proliferation were found, as in No. 2. Darkly staining colloid was present in some regions in the cortex of the ovotestis, but occurred in relatively small quantities. *The right gonad*, as was anticipated, proved to be a functional testis with every tubule in active spermatogenesis. It presented no abnormal features.

**No. 4.**—A White Leghorn hen, which was  $3\frac{1}{2}$  years old when obtained, had, to the surprise of its first owner, within a short time assumed the head furnishings of the male, had begun to crow and had exhibited a bellicose disposition. In its general attitude it behaved as a male towards hens and towards cocks but it did not tread. The spurs grew in length, the right one being at the time of the bird's death 1.8 cm., the left one 1.7 cm.; the comb was 5.8 cms. at its highest point but it never became entirely erect. The plumage remained completely henny save that three of the neck-hackle feathers were rather intermediate. On dissection there were found on the left a yellowish smooth-surfaced sex-gland of an irregular shape and measuring  $1.5 \times 5$  cms., a thin oviduct, 5 mm. in diameter, and a vas deferens.

*Histology.*—The gonad was found to be a cystic ovary with a heavy secondary growth of testicular tissue. It was divided into two parts, one of which consisted of ovarian stroma, cysts, atrophic tubules, and fibrous vascular cords, and the other of cysts and normal immature tubules. The two parts were separated by blood clots, groups of fat cells, and dense masses of fibrous tissue permeated by syncytial plain muscle fibres. The part composed of recognisable ovarian tissue contained, as we have said, numerous cysts which were mostly simple as in the ovotestis of Nos. 2 and 3, but were sometimes lined by ciliated columnar epithelium and were papilliferous. They contained the usual mucoid matter. No oöcytes were found, but the remains of old discharged or atretic follicles were common. These projected above the surface as ovoid structures and were formed of large groups of vacuolated cells embedded in dense fibrous tissue. These cells

## Honor B. Fell

had small round darkly staining nuclei, and yellow pigment granules were present in the cytoplasm between the vacuoles. The latter were spherical and were probably occupied by fat which, however, had not been preserved in material fixed in Flemming's solution. The hilar cords were fibrous and highly vascular, and the interstices contained much plasma together with scattered erythrocyte nuclei. The cortical region was thin except where large lobules of atrophic tubules occurred (fig. 17). These tubules were almost identical in structure, with the resting tubules described in the left gonad of No. 2, but were more degenerate. The cytoplasm was syncytial, fibrillar, and often scanty; the oval nuclei were situated at fairly wide intervals in a single layer within the basement membrane and contained a plasmosome. Mitotic figures occurred, but were rare, and no synaptic figures were seen. Occasionally a normal immature tubule with a central lumen and regularly disposed epithelium was met with. In many cases the spermatic tissue appeared to have been proliferated into a discharged or atretic follicle, and the intertubular spaces were occupied by groups of vacuolated pigment containing cells resembling those described in the old follicles (fig. 17). Ordinary "luteal" cells were also present and were readily distinguishable from the pigment containing cells by their larger and clearer nucleus, smaller vacuoles, and faintly staining cytoplasm. Many sex cords in process of transformation into "luteal" cells were seen. Elsewhere the tubules seemed to have been formed in the stroma, and in other areas in which there was less evidence of degeneration the intertubular tissue consisted only of loose fibrous strands, while the whole area was enclosed by fibrous walls suggesting that the tubules had been formed in a large cyst. The tubules were everywhere closely wedged together and often distorted in shape accordingly. Traces of proliferation of sex cords from the peritoneum could not be found.

The other portion of the gonad consisted of several large and numerous small cysts and typical young seminiferous tubules. The large cysts, which contained a small quantity of mucoid substance, were about 2 mm. in diameter and were lined by ciliated columnar epithelium with no papillæ. Some

## Histological Studies on the Gonads of the Fowl

of the small cysts which were probably less distended, showed the papilliferous structures and were lined by thicker epithelium. The seminiferous tubules were enclosed in a fibrous capsule which almost undoubtedly represented the remains of a large multilocular cyst. Comparison with the testis of a normal three months' chick showed an almost identical appearance in the two cases (*cf.* figs. 15 and 16). The shape and size of the tubules, their degree of convolution, the size of the lumen, and the cytological character of the epithelium were the same in both, and the only appreciable difference was the presence of a greater number of definitive spermatogonia in the normal testis. The tubules were bounded by a well-marked basement membrane and lined by a layer of high columnar epithelium composed of narrow cells with indistinct cell boundaries. A small but distinct lumen was present. The nuclei were small, oval, and situated close to one another in a peripheral zone; they contained numerous small granules and several large blocks of chromatin. Occasionally one or more larger cells occurred lying more centrally: these had a large round nucleus containing more chromatin granules than the other nuclei and were probably definitive spermatogonia. Mitotic figures were fairly common. Some of the tubules contained a central mass of cell debris which was usually giving rise to a concretionary body—a phenomenon which was also seen in the normal chick testis. One or two of the tubules were seen to branch. The intertubular tissue, unlike that of the normal chick testis, was extremely sparse, although the intervening spaces were often fairly wide; it consisted of a few fine fibro-cellular strands and numerous small blood vessels. In some parts a thin mucus was seen, which was probably part of the original cyst contents.

**No. 5.**—Like the previous, this bird was a White Leghorn hen, henny-feathered but with the head furnishings of a cock. The comb was 5.7 cms. at its highest point and completely erect. The right spur measured 1.6 cm., the left 1.7 cm. The sexual behaviour was indifferent: the bird did not lay, crow, or tread. On dissection, a small atrophied ovary was found on the left side; it was yellow in colour and most of its surface was flat. A small oviduct, 5 mm. in diameter, was present.

## Honor B. Fell

*Histology.*—Histological examination showed the ovary to be completely atrophied, and even degenerate oöcytes were not found. In places a few small irregular cavities containing coagulum and a few erythrocytes were present, which perhaps represented the remains of cystic follicles. The peripheral part of the gonad, where the oöcytes would normally have been situated, was occupied by atrophic tubules such as those described in the preceding member of the series. They were of irregular shape, closely packed together and contained loose degenerate cytoplasm and a few shrunken or hypertrophied nuclei (fig. 18). In some cases the basement membrane had been broken through and the germinal epithelium was being invaded by connective tissue. Material fixed by the Flemming and Mann-Kopsch methods show that large fat globules were often present. No mitotic or synaptic figures were seen. The germinal peritoneum showed, in most regions the characteristic histological changes which immediately precede the proliferation of sex cords. It was much thickened, the nuclei contained distinct polarised loops and the basement membrane was being penetrated. In some areas the basement membrane could not be made out, and the peritoneal cells seemed to be more or less continuous with the underlying tissue. The most central part of the ovarian cortex was principally occupied by large dense aggregates of polyhedral epithelial cells amongst which lay much deeply staining colloid substance (fig. 19). The cells had a large rather clear spherical nucleus with a conspicuous plasmosome and cytoplasm containing numerous mitochondria and globules of colloid substance presumably derived from the large masses of caseous material. In some areas the cells were arranged in closely compressed columns but usually they had no definite arrangement. Large numbers of the cells were in places undergoing transformation into "luteal" tissue in the manner described in the ovotestis of No. 2. Mitotic figures occurred but were not very common. The medullary zone had the usual fibrous vascular structure.

**No. 6.**—A White Leghorn hen, 3 years old, concerning which the owner wrote: "For some time she has been treading other hens exactly as would a cock bird." The bird was henny-feathered and had the head furnishings of the male:



## Histological Studies on the Gonads of the Fowl

the spurs were but 0.5 cm. in length. During all the time it was under observation it did not crow or tread other hens ; neither did it lay. On dissection, a "resting" ovary and oviduct were found.

*Histology.*—The gonad was found to be a cystic ovary in which the stroma was to a great extent replaced by undifferentiated sex cords and very young tubules. Numerous irregularly shaped cysts of the simple type described in Nos. 2 and 3 were present, but neither oöcytes nor old discharged follicles were seen. The sex cords and tubules were very closely packed together, the latter far more numerous than the former, but there was no sharp line of demarcation between the two as they graded into one another. The tubules were circular in cross-section and contained no central cavity ; they were enclosed by a well-developed basement membrane and the boundaries of the epithelial cells could be vaguely distinguished (fig. 20). The nuclei which were situated in close juxtaposition immediately within the basement membrane were large, spherical, and contained a plasmosome and several large chromatin granules which showed much variation in size and number in different regions. Mitotic figures were fairly numerous but no synapsis occurred. In some areas many tubules were degenerating through a rather peculiar process of liquefaction. The central protoplasm gave rise to an amorphous granular mass which was sometimes sharply limited from the peripheral protoplasm and sometimes merged into it gradually. The degeneration spread outwards and the colloid might finally occupy the whole tubule. The nuclei drifted into the fluid, shrank, and ultimately disappeared. In another form of degeneration tubules were seen to be more deeply stained than the rest and the epithelium was somewhat shrunken from the basement membrane ; in other tubules this shrinkage was more marked and the epithelium was finally reduced to a shrivelled mass lying in the centres or to one side of the tubules. Groups of luteal cells in every stage of formation from sex cords occurred throughout the gonad, and in places large areas of cords and small tubules were found all of which were undergoing this process. Occasionally a few larger atrophic tubules were seen with the usual scanty fibrillar

## Honor B. Fell

cytoplasm and scattered nuclei. Small groups of normal immature tubules resembling those described in No. 4 (fig. 15) were sometimes present at the periphery and appeared to occupy a cystic follicle. They were lined by a columnar epithelium composed of narrow cells with small oval nuclei and indistinct outline, and a small central cavity was always present.

Deeply stained streaks of colloid occurred in some regions and the transition between this and necrotic sex cords could be followed. Connective tissue cells were seen to lie among protoplasmic substance which stained yellow with iron hæmatoxylin and contained nuclei similar to those of the sex cords; numerous luteal cells were always present. In other regions normal sex cords were found among this material which stained more darkly, was more compressed, and had lost all structure. The final stage was represented by the dense streaks wedged in between normal cords which had been described in the gonads of all the previous members of the series. Examination of the peritoneal epithelium did not reveal any of those changes which characterise an incipient sex cord formation, and it would appear, therefore, that the production of cords from this source had ceased. New spermatic tissue probably arose from multiplication of the cells of the cords previously proliferated. The Wolffian body consisted of a number of ducts lined by ciliated columnar epithelium composed of cells with very definite boundaries and spherical nuclei (fig. 21). The lumina of the ducts were usually occupied by coagulated fluid. A rete lined by rather indefinite cubical cells was in close relationship with the ducts.

**No. 7.**—Like the three preceding members of the series the bird was a White Leghorn, 3 years old. Its plumage was henny, its head furnishings large and vascular, its spurs mere buttons. The bird did not lay and did not crow or tread. On dissection, there were found a small yellow atrophied ovary measuring 2 cms.  $\times$  0.5, and a small, straight, thin oviduct.

*Histology.*—The ovary was found to consist of a rather thick cortical region and a few very fibrous central cords. Numerous shrunken cysts projected above the surface, representing the remains of follicles, but oöcytes were absent. The

## Histological Studies on the Gonads of the Fowl

cortical portion was composed partly of connective tissue stroma and partly of sex cords which varied considerably in size (fig. 24). In places they were large enough to be regarded as small tubules such as those described in No. 6, and consisted of a basement membrane lined by polyhedral epithelial cells which completely filled the lumen. Such tubules were sometimes seen to be in connection with the thickened peritoneal epithelium from which they were evidently being proliferated. A few were in colloid degeneration and others gave rise to conspicuous groups of "luteal" cells. Large areas were occupied by smaller cords usually not more than one cell in thickness, which towards the centre lost their characteristic structure and formed a close syncytium of irregularly disposed cells. Many of these were either in degeneration or in process of transformation into rather compressed "luteal" cells. Other regions of the cortex were mainly composed of typical ovarian stroma, in which were seen large numbers of small degenerating "luteal" cells and a few necrotic sex cords.

**No. 8.**—The bird was a Light Sussex, 3 years old, concerning which in the spring of 1921 its owner wrote: "This bird laid for us up to the time of coming into the moult last autumn (1920) and since then has assumed a male appearance; its appendages have developed, but it does not crow; it has ceased entirely to lay." The bird did not crow or lay all the time it was under observation. Its plumage remained henny but the head furnishings were male in type. The spurs were small; the right being 1.7, the left 1.5 cms. long. In 1922 it went broody and raised chickens.

*Histology.*—The histological structure of the gonad was found to be that of an atrophic ovary with numerous lobules of sex cords and young seminiferous tubules. The cortex of the ovary except when occupied by spermatic tissue was very thin and was composed of the usual form of ovarian stroma. An occasional cystic follicle was met with and more rarely the remains of a small oöcyte which had passed through the ordinary process of involution. The vascular cords presented the same appearance as those of the normal ovary. In some areas the peritoneal epithelium was thickened, the nuclei contained well-marked polarised loops, and incipient sex cords were

## Honor B. Fell

beginning to grow inwards into the stroma in the manner previously described. The majority of the sex cords were rather large and might almost have been described as young tubules (fig. 22). Their histological character was precisely similar to that of the cords in the ovary of No. 6 (fig. 20). They usually occurred as large spherical or ovoid masses which projected from the surface of the ovary, and which on macroscopic examination had been regarded as discharged, or atretic follicles; it seemed probable that the cords had been proliferated into such structures. They also occurred in the stroma, although this was uncommon. In places groups of larger atrophic tubules were found in which the lumen was occupied by scanty syncytial cytoplasm, and the oval nuclei were arranged at wide intervals immediately within the basement membrane. One or more normal immature tubules were also often found in such groups and had the usual high columnar epithelium and a small central cavity. "Luteal" cells occurred in great numbers and their origin from sex cords was excellently demonstrated in Mann-Kopsch preparations, in which the "luteal" cells were very deeply impregnated and stood out black against the surrounding tissue. As is the case in the embryo, the first stage in their development appears to be an increase in the number of mitochondria, followed by the formation of numerous small clear vacuoles which, according to Nonidez, are occupied by highly soluble fat. The nucleus becomes reduced in size and is stained and impregnated more deeply than in the neighbouring cells.

### 4. Discussion.

**The Origin of the Sex Cords.**—The histological study of the gonads in the foregoing series of hermaphrodite fowls leaves little doubt that the birds were originally hens, the ovaries of which, for certain physiological reasons which have been discussed elsewhere in a communication by F. A. E. Crew, atrophied at some period of life and were then invaded by peritoneal tissue in the form of epithelial cords. In some birds this tissue consummated development by giving rise to mature seminiferous tubules as in Nos. 2 and 3, and in others gave rise to areas of undifferentiated epithelial cords which frequently

## Histological Studies on the Gonads of the Fowl

developed into tubules of an embryonic or immature type. Epithelial structures similar to the undifferentiated sex cords have been recorded by other authors and have been interpreted in various ways. Shattock and Seligmann, 1907, in their account of a case of incomplete hermaphroditism in the fowl, describe "a close plexus of epithelial elements . . . grouped together in solid columns which are nowhere broad," and regard them as the female constituent of the gland and as representing Pflüger's tubes. Pearl and Curtis, 1909, in reporting a similar case of hermaphroditism in the fowl, refer, in their description of the right gonad of this specimen, to "small cellular rods" which "might be considered tubes without lumen," and which they regard as tubular in character. The fact that the transformation of the cords into mature seminiferous tubules could be followed in all its stages in Nos. 2 and 3 of the present series, leaves little doubt of the accuracy of the second view.

As regards the origin of the sex cords, the histological evidence is such as to prove beyond doubt that they were sometimes proliferated from the peritoneal epithelium covering the gonad. Traces of this proliferation were met with in most of the ovaries, and the complete process was beautifully seen in the left gonad of No. 2, which also demonstrated the homology between the undifferentiated cords, atrophic and mature tubules, which would otherwise have been difficult to establish beyond criticism. It must be borne in mind, however, that there are two other peritoneal elements in the ovary which normally remain quiescent or degenerate. These are the remnants of the medullary cords, the distal portions of which are largely incorporated in the thecæ of the ovarian follicles and the granulosa cells of atretic follicles. Although there are no facts to show that either of these tissues takes part in the formation of testicular tubules, the possibility that they do so cannot be eliminated, since conditions which would stimulate the growth and differentiation of the germinal peritoneum itself, might also favour further development of its intra-ovarian derivatives. Thus in the case of No. 4 the typical immature tubules which were found in what had almost certainly been a large cystic follicle, might have been proliferated into the cyst from the overlying peritoneum, or might have been formed

## Honor B. Fell

from the granulosa cells of the original follicle. In this connection it is interesting to note that Gatenby in his paper, "The Transition of Peritoneal Epithelial Cells into Germ Cells in some Amphibia Anura, especially in *Rana temporaria*," describes the occurrence of nests and cysts of germ cells developing in the follicles of atretic oöcytes, although, according to this author, the main source of new germ cells in the adult amphibian ovary is the peritoneum. Pearl and Boring regard the tubules in the gonads of their hermaphrodite fowls as being formed by hypertrophy of "the sex cords in the core of the gonad," but offer no histological substantiation of this hypothesis.

The position is briefly this: there is conclusive histological evidence to show that the testicular tissue was in part, at least, derived from a proliferation of sex cords from the peritoneum, whereas there is none in support of the view that it was derived from granulosa cells or the remains of the medullary cords; but the possibility that this was to a certain extent the case must be admitted in absence of further evidence to the contrary, since on theoretical grounds it seems not wholly unlikely.

**The Secondary Formation of Spermatic Tissue in the Ovary compared with the Embryonic Development of the Testis.**—Firket gives the following account of the development of the testis in the fowl. The first trace of the gonad is seen very early in embryonic life as a thickening of the peritoneal epithelium in the angle between the mesentery and the Wolffian body. This rudiment enlarges to form a ridge composed of mesenchymatous tissue, the surface of which is covered by the columnar germinal epithelium from which, in the next stage of development, a number of invaginations are formed—the sex cords of the first proliferation. In the female these give rise to the medullary cords which ultimately abort, and in the male they form the seminiferous tubules. The primary germ cells migrate into the epithelium of the germinal ridge and finally into the sex cords, where they appear as conspicuous rounded cells. The cords which have a definite basement membrane increase in size and anastomose to form an epithelial network. Up to this point sex is indistinguish-

## Histological Studies on the Gonads of the Fowl

able, but the period of differentiation then begins, and in the tubes the cords steadily enlarge until they may be regarded as small seminiferous tubules. These contain two types of cells: (1) Small cells with oval nuclei arranged immediately within the basement membrane, and (2) large cells with a big clear spherical nucleus which, according to Firket, represent both primary germ cells and also secondary germ cells derived from the small cells. The tubules have no lumen, the cell limits are indistinct, and both the description and figures of these structures show their striking resemblance to the small tubules which occur in the ovaries of fowls Nos. 6, 7, and 8 of the present series (figs. 20, 23, 24). Following the period of differentiation is the period of pre-spermatogenesis, when Sertoli cells are differentiated from the small epithelial cells, and the spermatogonia, after repeated mitoses, give rise to primary spermatocytes. The final stage in the development of the tubules is spermatogenesis, in which the secondary spermatocytes are produced.

Having briefly outlined the course of development of the seminiferous tubules in the normal embryonic testis, we may now compare this process with what we know of the secondary formation of spermatic tissue in the ovaries of the abnormal hens; the correspondence is close. In both the embryo and the fowls the first stage in the development of germinal tissue is represented by the enlargement of the cells of the germinal peritoneum, followed by the invagination of the epithelium at various points to form sex cords whose histological character is almost identical in the two cases. In both the cords are composed of polyhedral epithelial cells enclosed by a definite basement membrane, although it was noticeable that the cells of the sex cords and small tubules of the abnormal ovaries for the most part resembled the spermatogonia rather than the small germinative cells of normal embryonic cords; the diameter of the cords is the same in both cases, and in both the sex cords anastomose with one another to form an epithelial network permeating the connective tissue subjacent to the peritoneum. In the gonads of Nos. 6, 7, and 8 of the series the cords, as already stated, had enlarged to form tubules of the characteristic embryonic type. The rate and degree of

## Honor B. Fell

differentiation of testicular tissue in the hermaphrodites is, however, extremely variable. In some regions of the left gonads of Nos. 2 and 3 differentiation began in the peritoneum, in which typical pachytene figures were not uncommon, and the majority of the cells of the newly proliferated sex cords and young tubules were primary spermatocytes. This is not the case even in the developing testes of males of the early maturing breed which Firket employed in his researches, in which spermatocytes are described as beginning to appear at about the twentieth day of incubation, when the tubules are already fairly well developed. In most of the hermaphrodite gonads, however, differentiation of the cords was absent or slight, and mitotic figures were not found. Such cords enlarged to form the embryonic tubules that have been described, and finally gave rise to the immature (and often atrophic) tubules which were present in variable numbers in the gonads of all the first seven birds of the series, and which, in the undegenerate condition, only differed from those in the testis of a normal young cockerel of a slowly maturing breed, in the complete absence of synapsis and the comparative rarity of spermatogonia.

An interesting point of resemblance between the embryonic testis and the neoplastic spermatogenic tissue is the origin of the "luteal" cells. According to the work of Nonidez on the "luteal" tissue of hen-feathered cocks, the cells are formed by the fatty infiltration of some of the sex cords and young tubules. As has been shown above, this is precisely what takes place in the gonads of the hermaphrodite fowls, although on a much greater scale, so that sometimes whole areas of sex cords are seen to be undergoing this transformation as in Nos. 2, 6, and 7. If the "luteal" cells are merely the products of fatty degeneration of the sex cords, it is difficult to understand how they can exercise the endocrine function attributed to them by Morgan and by Pearl and Boring. The degenerative character of the process is indicated by the fact that in the areas in which it is taking place, the unaffected sex cords are usually completely undifferentiated and frequently aborting by other means. On the other hand, the cytological character of the cells does not entirely correspond with that of cells in ordinary fatty degeneration, *e.g.* the granulosa cells



## Histological Studies on the Gonads of the Fowl

of an atretic follicle, in which the cytoplasm does not show the strikingly dense impregnation with the Mann-Kopsch fixation which is so characteristic of the "luteal" cells (fig. 23). The black appearance of the latter with this technique appears to be due to the presence of large numbers of mitochondria and granules of mitochondrial origin situated between the vacuoles from which the fatty material is usually completely dissolved away. The theory that the "luteal" cells are responsible for the exhibition of female plumage receives some support from the fact that "luteal" cells were present in the gonads of all the birds except No. 1, in the testis of which they were not found, and this individual alone showed completely male plumage. In the case of all other fowls the plumage, with the exception of a few intermediate feathers, were of the female type, even when as in the gonads of Nos. 2 and 3, mature testicular tissue was present.

**The Formation of Testicular Tissue in the Ovaries of Abnormal Hens in Relation to the Question of the Origin of the Germ Cells.—**The problem of the origin of the germ cells is one that has interested biologists for many years, but even yet the matter is, as regards vertebrates, still *sub judice*. At the present time two views are held: the first, which was originally put forward by Waldeyer, is that the cells have a somatic origin, and are derived from the epithelial cells of the germinal peritoneum investing the gonad; the second, enunciated by Nüssbaun, is that the germ cells are segregated very early in embryonic life and subsequently migrate to the germinal ridge where, at a later period, they develop into male or female gametes; some investigators subscribe to both views and hold that the germ cells have a double origin. Either hypothesis is supported by considerable histological evidence. The early formation and subsequent migration of the germ cells has now been demonstrated in species of every vertebrate phylum. In vertebrates it is usually found that the germ cells arise in the entoderm, as a rule before embryo formation, and later migrate into the embryo by routes varying in different species, until they come to lie in those areas of peritoneum at the base of the mesentery which represent the site of the future genital glands. This phenomenon, which has been observed by

## Honor B. Fell

Wheeler, Beard, Dodds, Swingle, Allen, Dustin, Rubaschkin, Swift, Firket, and many others, can no longer be denied, but the ultimate fate of the primordial germ cells after their arrival in the germinal peritoneum is still a matter of dispute. In the case of many members of invertebrate phyla, the origin of the definitive germ cells of the adult from the early primary germ cells is fully established. This continuity has been shown in many species of the Arthropoda, of which the best example is the pædogenetic fly, *Miastor*, in which the primordial germ cell is formed very early in cleavage, viz., at the 8-cell stage. The descendants of this cell can be followed throughout their entire cycle without difficulty owing to their large size and conspicuous appearance. The same continuity has long been known in Nematodes, *e.g.* *Ascaris* and *Sagitta*, but as yet has not been conclusively demonstrated in a single vertebrate species.

Those who believe that the gonocytes of the adult are formed from the germinal epithelium, maintain that most or all of the primary germ cells degenerate and are replaced by secondary germ cells of mesodermal origin. As Swingle points out, most of the opponents of this view have, until recently, "been at fault by contenting themselves with tracing the primordial sex cells into the genital glands and there leaving them, with the assumption that they persist and form the sexual elements of the adult organism." Even those observers who have followed the fate of the germ cells during the later development of the gonad differ, however, in their conclusions. Swingle, as a result of his work on the bull frog, "prefers to believe that some cells of the primordial germ cell line persist unchanged through the phase of maturation and degeneration, and ultimately, by repeated mitoses, are the chief and probably only contributors to the cells of the definitive sexual line," but admits that "odd as it may seem it is not impossible, in the light of conditions described above for the bull frog larvæ, that the primordial germ cells of vertebrates . . . may possibly be found upon further investigation to contribute little if any to the definitive sex products of the adult organism." Dustin, in his researches upon the gonocytes of *Chrysemis*, state that the number of primary gonocytes which reach their destination

## Histological Studies on the Gonads of the Fowl

in the germinal epithelium is very reduced and a new set of sex cells of mesodermic origin is proliferated from the germinal epithelium. De Winiwarter and Sainmont, working upon the cat, deny that the primordial germ cells are true germ cells, and maintain that the latter are derived from the germinal epithelium only, while the former are "des cellules hypertrophiées temporairement et n'ont rien de commun avec l'ovogenèse." Firket, in his study of the testes of young albino rats, concludes that two generations of germ cells exist, of which the first disappears before the second arises, and insists that the secondary germ cells, or spermatogonia, "can only be derived from the small epithelial cells, as they are at this stage the only type of cells present in sufficient number in the sex cord." In the case of the chick, the primordial germ cells, according to Swift, arise in the entoderm anterior and antero-lateral to the developing embryo, and a proportion of these are later carried to the genital anlage partly by amœboid migration and partly by the blood stream. Most find their way into the thickened germinal peritoneum. A certain number are carried inwards with the proliferating medullary cords where, according to Firket, they pass through synapsis into the resting phase and degenerate. Some remain in the peritoneum and, according to Swift, "become the definitive ova, while the peritoneal cells of the germinal epithelium, present in the cortical cords, develop the follicular epithelium." On the other hand, Firket writes: "Il y a néoformation d'oocytes dans la zone cortical aux dépens d'éléments dérivés de l'épithélium germinatif; ils donnent la majorité des oocytes qui arrivent à maturité," but "il n'y a pas de raison d'admettre que certains gonocytes primaires ne peuvent, en petit nombre il est vrai, devenir des oocytes murs." In the case of the fowl, Firket's view that gonocytes are derived chiefly from the germinal epithelium receives confirmation from the result of the present investigation. It seems almost certain that the polarised loops in the nuclei of the enlarged peritoneal cells in the ovaries of the hermaphrodite fowls represent very early meiotic phases, since every stage intermediate between nuclei with paired polarised loops and typical pachytene figures are found in the peritoneum. If this

## Honor B. Fell

is so, it is evident that all the cells in the large thickened areas of the germinal epithelium must be potential gonocytes, which is also indicated by the fact that in regions of rapid differentiation sex cords, still continuous with the peritoneum, are often wholly composed of primary spermatocytes in the unmistakable pachytene stage. On the theory of the non-somatic origin of germ cells these facts could only be explained by the assumption that in the adult bird large areas of the ovarian peritoneum are derived from a few isolated primordial germ cells stranded there after the formation of the cortical cords—an hypothesis which has some theoretical possibility but hitherto no histological justification. The simpler and far more probable interpretation is that we have here a case of direct transition of ordinary somatic peritoneal cells into germ cells, a conclusion which is supported by Gatenby's work on the neof ormation of germinal tissue in the ovaries of the Anura, to which we have already referred. This observer describes the appearance in early spring of extensive thickenings of the germinal peritoneum which "become ovariform germ pockets containing newly formed germ cells in all stages," and which are absent in the ovaries of animals killed during the winter months. Gatenby figures all stages intermediate between normal peritoneal cells and typical gonocytes.

**The Factors controlling Localisation of Spermatic Tissue in the Hermaphrodite Gland.**—In the great majority of recorded cases of hermaphroditism in which an ovotestis is present, it is found that the bulk of the testicular tissue occupies a position median to the ovarian portion of the gonad. It would appear from the present study that this localisation is due partly to mechanical, partly to physiological causes. The least dense portion of the ovarian stroma in the fowl is the hilar region, which consists merely of a loose network of anastomosing vascular cords, whereas the cortex is composed of dense cellular connective tissue. In the shrunken atrophic ovary the denseness and thickness of the cortical stroma is usually greatly intensified, and in most cases of hermaphroditism it is in connection with such abortive organs that testicular tissue is found. It is probable that neoplastic growth would find such a medium unfavourable for two reasons. In the first

## Histological Studies on the Gonads of the Fowl

place it would present considerable mechanical resistance, and in the second place the invading epithelium would have to compete with the innumerable phagocytic cells present in this peripheral region. The mortality among the invading cells would, therefore, be high, and differentiation and growth correspondingly slow, since it would require repeated proliferations from the germinal epithelium before the testicular tissue could become sufficiently firmly established to pursue its further development. On the other hand, when once the sex cords had penetrated to the loose hilar portion of the ovary, they would meet with very slight mechanical hindrance, and, owing to the fact that the anastomosing cords are composed chiefly of fibrous tissue with relatively few cell elements, phagocytic resistance would also be considerably less. Under these circumstances the testicular tissue in the central regions would rapidly outstrip in growth and differentiation the earlier formed cords in the periphery, as is the case in the left gonads of Nos. 2 and 3 of this series.

Evidence for this view is as follows :—

(1) In the ovotestis of No. 2, sex cords frequently invade small cystic follicles and there give rise to typical spermatocytes, whilst the germinal tissue in the surrounding stroma is sometimes completely undifferentiated.

(2) In the ovary of No. 4, the stroma is permeated with tubules which, with a few exceptions, are all in process of atrophy (fig. 17). In the "tumour," on the other hand, the tubules, though of the same appearance as those in the stroma, are completely normal, and show numerous mitoses; they are immature owing to general metabolic causes which have been discussed in Crew's communication. There is, however, no intertubular tissue in the "tumour" except a few fine strands supporting small blood vessels, and, as has been already stated, the structure probably represents a large ovarian cyst into which sex cords have been proliferated.

(3) In the case of No. 2, in which metabolic conditions were presumably favourable for differentiation of the sex-cord cells since mature, functional tubules are found in both gonads; the areas in which completely undifferentiated cords occur either show dense stroma between the cords, in which case the latter

## Honor B. Fell

are usually degenerating, or else streaks of darkly staining amorphous material which is found to represent the remains of (a) pre-existing ovarian stroma obliterated by the sex cords, and (b) earlier unsuccessful proliferations of cords.

(4) In those cases of hermaphroditism in the fowl in which a small right gonad is present, it is commonly found that the seminiferous tubules are more advanced and show less regional variation in development than do those of the left gonad. This is probably owing to the fact that in the majority of cases there was no pre-existing ovarian stroma to impede the growth of neoplastic tissue, and the tubules could, therefore, develop under the more or less ideal condition of embryonic life.

(5) In pathology it is a familiar fact that fibrous tissue is highly resistant to tumour growth, which may become completely checked by the formation of a fibrous capsule.

From the above facts, it seems justifiable to conclude that the new spermatic tissue will prosper best in any situation in which there is no morphological impediment, and that it is usually most abundant in the median portion of the gonad, because the facilities for development are best in that situation.

### 5. Summary and Conclusions.

(1) The histological study of the gonads of the eight birds described showed them to be hens at different stages in sex reversal. No. 1 had changed completely from a fertile hen to a fertile cock which was almost indistinguishable from a normal male. The left gonads of Nos. 2 and 3 were found to contain mature seminiferous tubules, and a small testis was in each case present on the right side. The ovary of No. 4 was largely occupied by typical immature tubules, that of No. 5 by atrophic immature tubules, and those of Nos. 6, 7, and 8 by sex cords and small tubules of an embryonic type.

(2) In every case the development of testicular tissue was preceded by ovarian atrophy or disease. Oöcytes were found only in the left gonad of No. 2, and then only in small numbers.

(3) The mode of formation of the spermatic tissue appeared to be almost identical with the embryonic process, as follows:  
1. A thickening of the germinal epithelium was produced by the enlargement of the component cells, and sometimes by the

## Histological Studies on the Gonads of the Fowl

formation of several layers; 2. columns of cells, or sex cords, proliferated inwards from the peritoneum; 3. these enlarged to form tubules. The possibility that other peritoneal derivations, viz., the remains of the medullary cords and the granulosa cells of atretic follicles, play some part in the formation of new germinal tissue is admitted, although no histological evidence of this was found.

(4) Enormous numbers of typical "luteal" cells were present in all the gonads, with the exception of those of No. 1, and were found to be derived from undifferentiated sex cords in precisely the same way as in the embryo and young chick. The histological evidence indicated that the process of transformation of the sex cords into "luteal" cells was one of degeneration, but, on the other hand, the theory that these cells are responsible for the exhibition of female plumage is supported by the fact that in the gonads of the only cock-feathered individual (No. 1) such cells were not found.

(5) The problem of the origin of germ cells was briefly reviewed, and it was concluded that in the present instance the newly formed gonocytes were of somatic (peritoneal) origin, since the nuclei of all the cells of the germinal epithelium contained polarised loops of chromatin, often intimately twisted, which appeared to represent early meiotic figures, and which were linked by a series of intermediate stages with spermatocytes in the characteristic contraction phase of the pachytene.

(6) The degree of differentiation of the neoplastic germinal tissue was highly variable 1. in the different individuals, and 2. in the gonad of the same bird. This is probably due in the former case to metabolic conditions which have been discussed elsewhere in a paper by F. A. E. Crew, and in the latter to the morphological environment of the sex cords, the dense regions of the pre-existing ovarian stroma being a less favourable medium for growth and differentiation than the looser parts. On this latter supposition was explained the fact that in most cases of hermaphroditism in which an ovotestis is present, the spermatic tissue is described as occurring median to the ovarian portion. Probably the reason for this is that

## Honor B. Fell

in the atrophic ovary the cortex is usually composed of dense stroma, while the hilar portions consist of loose fibrous cords which would offer but little resistance to growth.

### 6. References.

- <sup>1</sup> Allen, B. M. (1906), "The Origin of the Sex Cells of *Chrysemis*," *Anat. Anz.*, **29**.
- <sup>2</sup> Allen, B. M. (1909), "The Origin of the Sex Cells of *Amia* and *Lepidosteus*," *Anat. Rec.*, **3**.
- <sup>3</sup> Beard, J. (1903), "The Germ Cells, Part 1, *Raja batis*," *J. Anat. and Phys.*, **38**.
- <sup>4</sup> Beard, J. (1905), "A Morphological Continuity of Germ Cells as the Basis of Heredity and Variation," *Bull. Iowa Inst.*
- <sup>5</sup> Bond, J. (1913), "On a Case of Unilateral Development of Secondary Male Characters in a Pheasant, with Remarks on the Influence of Hormones in the Production of Secondary Sex Characters," *Journ. Gen.*, **3**.
- <sup>6</sup> Brandt (1889), "Anatomisches und Allgemeines über die Sogenannte Hahnenfedrigkeit und über anderweitige Geschlechtsanomalien bei Vögeln," *Zeitschr. F. Wissen. Zool.*, **48**.
- <sup>7</sup> Cole, L. J., and Lippincott, W. A. (1919), "The Relation of Plumage to Ovarian Condition in a Barred Plymouth Rock Pullet," *Biol. Bull.*, **33**, No. 3.
- <sup>8</sup> Crew, F. A. E., "Studies in Intersexuality—II. Sex Reversal in the Fowl" (in the press).
- <sup>9</sup> Dodds, G. S. (1910), "Segregation of the Germ Cells of the Teleost *Lophius*," *Journ. Morph.*, **21**.
- <sup>10</sup> Dustin, A. P. (1910), "L'origine et l'évolution des Gonocytes chez les Reptiles (*Chrysemis marginata*)," *Arch. de Biol.*, **25**.
- <sup>11</sup> Firket, J. (1914), "Recherches sur l'organogenèse des glandes sexuelles chez les oiseaux," Part 1, *Arch. de Biol.*, **29**.
- <sup>12</sup> Firket, J. (1920), *Ibid.*, Part 2, *Arch. de Biol.*, **30**.
- <sup>13</sup> Firket, J. (1920), "On the Origin of Germ Cells in Higher Vertebrates," *Anat. Rec.*, **18**.
- <sup>14</sup> Gatenby, J. B. (1916), "The Transition of Peritoneal Epithelial Cells into Germ Cells in some Amphibia Anura, especially in *Rana temporaria*," *Q.J.M.S.*, **61**.
- <sup>15</sup> Hartman and Hamilton (1922), "A Case of True Hermaphroditism in the Fowl, with Remarks upon the Secondary Sex Characters," *J.E.Z.*, **33**, No. 2.
- <sup>16</sup> Hegner, R. W. (1900), "The Origin and Early History of the Germ Cells in some Chrysomelid Beetles," *Journ. Morph.*, **20**.
- <sup>17</sup> Hegner, R. W. (1914), *The Germ-Cell Cycle in Animals*, Macmillan.
- <sup>18</sup> Morgan, T. H. (1919), *The Genetic and Operative Evidence relating to Secondary Sexual Characters*, Carnegie Institution of Washington.
- <sup>19</sup> Morgan, T. H. (1920), "The Endocrine Secretion of Hen-feathered Fowls," *Endocrinol.*, **4**.
- <sup>20</sup> Nonidez, J. F. (1920), "Studies on the Gonads of the Fowl—I. Hæmatopoietic Processes in the Gonads of Embryos and Mature Birds," *Amer. Journ. Anat.*, **28**, No. 1.
- <sup>21</sup> Nonidez, J. F. (1922)—II. "El tejido intersticial del ovario," *Volumen Jubilar*, de S. Ramon y Cajal, Madrid.
- <sup>22</sup> Nonidez, J. F. (1922)—III. "The Origin of the So-called Luteal Cells in the Testis of Hen-feathered Cocks," *Amer. Journ. Anat.*, **31**, No. 2.
- <sup>23</sup> Pearl, R., and Boring, A. (1917), "Sex Studies—IX. Interstitial Cells in the Reproductive Organs of the Chicken," *Anat. Rec.*, **18**.



# Histological Studies on the Gonads of the Fowl

- <sup>21</sup> Pearl, R., and Boring, A. (1918)—X. "The Corpus Luteum in the Ovary of the Chicken," *Amer. Journ. Anat.*, **23**.
- <sup>22</sup> Pearl, R., and Boring, A. (1918)—XI. "Hermaphrodite Birds," *J.E.Z.*, **25**.
- <sup>23</sup> Pearl, R., and Curtis, M. (1909), "Studies on the Physiology of Reproduction in the Domestic Fowl—III. A Case of Incomplete Hermaphroditism," *Biol. Bull.* **17**.
- <sup>24</sup> Poll, H. (1908), "Zur lehre von den sekundären sexualcharakteren," *Sitz. Ges. Nat. Fr.*, Berlin.
- <sup>25</sup> Rubaschkin, W. (1907), "Über das reste auftreten und Migration der Keimzellen bei Vögelebryonen," *Anat.*, **85**.
- <sup>26</sup> Smith, G., and Thomas, R. H. (1913-14), "On Sterile and Hybrid Pheasants," *Journ. Gen.*, **3**.
- <sup>27</sup> Swift, C. H. (1915), "Origin of the Definitive Sex Cells in the Female Chick, and their Relation to the Primordial Germ Cells," *Amer. Journ. Anat.*, **18**.
- <sup>28</sup> Swift, C. H. (1916), "Origin of the Sex Cords and Definitive Spermatogonia in the Male Chick," *Amer. Journ. Anat.*, **20**.
- <sup>29</sup> Swingle, W. W. (1921), "The Germ Cells of Anurans—I. The Male Sexual Cycle of *Rana Catesbeiana* Larvæ," *J.E.Z.*, **32**.
- <sup>30</sup> Shattock and Seligmann (1906), "An Example of True Hermaphroditism in the Domestic Fowl, with Remarks on the Phenomenon of Allopterism," *Trans. Path. Soc., Lond.*, **57**.
- <sup>31</sup> Shattock and Seligmann (1907), "An Example of Incomplete Glandular Hermaphroditism in the Domestic Fowl," *Proc. Roy. Soc. Med.*, **1**, Part 3.
- <sup>32</sup> Tichomirow (1887), "A Contribution to the Problem of Hermaphroditism in Birds," *Proc. Nat. Hist. Soc.*, **52**, No. 3, Moscow.
- <sup>33</sup> Wheeler, W. M. (1899), "The Development of the Urinogenital Organs of the Lamprey," *Zool. Jahr.*, **18**.
- <sup>34</sup> De Winiwarter, H., and Sainmont, G. (1909), "Nouvelles Recherches sur l'ovogenèse et l'organogenèse de l'ovaire des Mammifères (chat)," *Arch. de Biol.*, **24**.


## 7. Description of Plates.

b.m. . . .	Basement membrane.		l.c. . . .	Luteal Cell.
c.g. . . .	Colloid globule.		ov. st. . .	Ovarian stroma.
g. . . .	Golgi apparatus.		spc. . . .	spermatocyte.

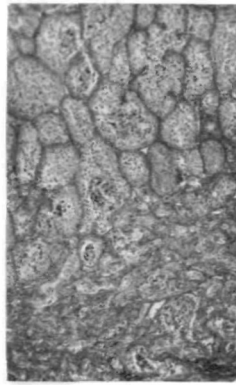
- FIG. 1.—No. 1. Section of testis. × 46-6.
- FIG. 2.—Section of testis of sterile cock. × 46-6.
- FIG. 3.—No. 2. Section of left gonad taken from the periphery of the organ to show clusters of cystic follicles. × 46-6.
- FIG. 4.—Same. Section taken from the central region. Note the sex cords and small seminiferous tubules in the lower half of the figure, and the functional tubules in the upper half. × 46-6.
- FIG. 5.—Same. (Fixation: Allen's solution; stain: iron hæmatoxylin.) Drawing to show proliferation inwards of sex cords from thickened peritoneum. Note the ruptured displaced basement membrane (b.m.), the polarised loops of chromatin in the nuclei of the epithelial cells, and the spermatocytes (spc.) in the characteristic contraction phase of the pachytene.
- FIG. 6.—Same. (Fixation: Allen's solution; stain: iron hæmatoxylin.) Peritoneal cell drawn under high power. Note the twisted loops of chromatin.
- FIG. 7.—Same. (Fixation: Flemming's solution less acetic acid; stain: iron hæmatoxylin.) Drawing of peritoneum showing four spermatocytes, one of which (a) has been enlarged to the same magnification as fig. 6.

## Honor B. Fell

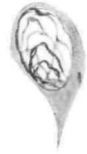- FIG. 8.—Same. (Fixation: Flemming's solution less acetic acid; stain: iron hæmatoxylin.) Drawing of two typical undifferentiated sex cords. Note the large nucleus, with plasmosome, and numerous mitochondria.
- FIGS. 9-11.—Same. (Fixation: Allen's solution; stain: iron hæmatoxylin.) Drawings to show the transformation of sex cords into typical "luteal" cells. In fig. 10 several adjacent cords are undergoing the same process.
- FIG. 12.—No. 2. Right gonad. On the left functional tubules are seen, while on the right they are atrophic and somewhat resemble those of the testis of the sterile cock (fig. 2).  $\times 46\text{-}6$ .
- FIG. 13.—No. 3. Section of left gonad (ovotestis). Note the row of small oöcytes at the periphery and the large functional seminiferous tubules to the left.  $\times 46\text{-}6$ .
- FIG. 14.—Same. (Fixation: Da Fano's silver impregnation method; stain: safranin.) Drawing to show sex cord with spermatocytes (spc.). The filamentous mitochondria and Golgi apparatus (g.) are seen.
- FIG. 15.—No. 4. Section of immature tubules in "tumour."  $\times 260$ .
- FIG. 16.—Section of the testis of a normal Rhode Island Red  $\times$  Light Sussex Cross-bred Chick. Note the close resemblance between the tubules in figs. 15 and 16.  $\times 260$ .
- FIG. 17.—No. 4. Section of ovarian stroma largely replaced by atrophic tubules. A few normal immature tubules are also seen. Numerous vacuolated pigment containing cells (v.c.) lie in the intertubular tissue suggesting that the tubules had been formed in an old discharged or atretic follicle.  $\times 60$ .
- FIG. 18.—No. 5. Section of ovary showing aborting immature tubules (*cf.* fig. 17).  $\times 260$ .
- FIG. 19.—Same. (Fixation: Flemming's solution less acetic acid; stain: iron hæmatoxylin.) Drawing showing the polyhedral epithelial cells which occur in large masses in the centre of the gonad. Note the deeply staining amorphous material, some of which is seen in the cytoplasm (cg.) along with numerous mitochondria.
- FIG. 20.—No. 6. Section showing large sex cords and tubules of an embryonic type.  $\times 260$ .
- FIG. 21.—No. 6. Section of parovarium.  $\times 260$ .
- FIG. 22.—No. 7. Section of ovary showing numerous young tubules composed of undifferentiated epithelial cells (*cf.* fig. 20).  $\times 260$ .
- FIG. 23.—Same. (Fixation: Mann-Kopsch method; unstained.) Section of ovary showing deeply impregnated "luteal" cells which are being formed from the sex cords.  $\times 260$ .
- FIG. 24.—No. 8. Section of ovary showing stroma with sex cords and young tubules.  $\times 260$ .



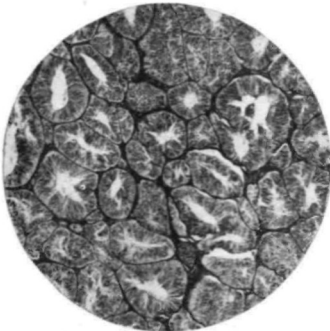
1



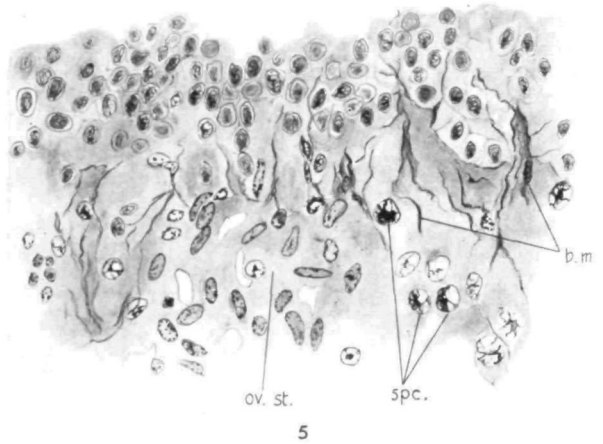
4



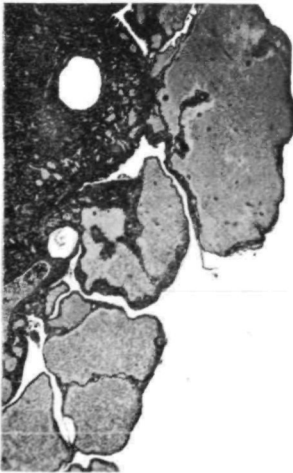
6



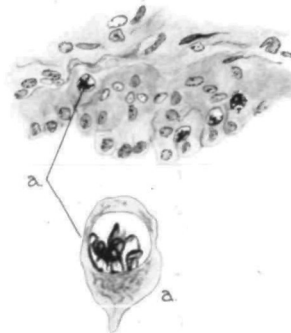
2



5

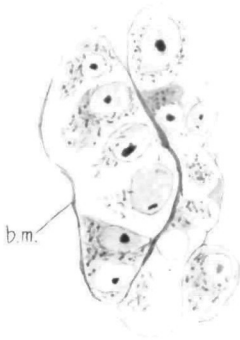


3

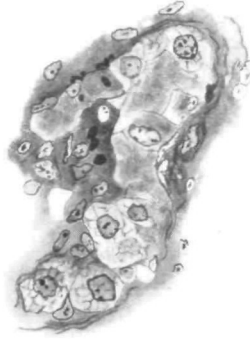

7

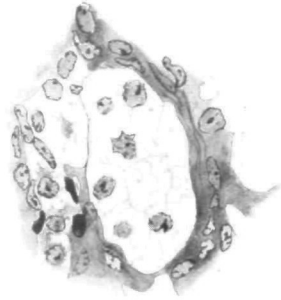HISTOLOGICAL STUDIES ON THE GONADS OF THE FOWL.—HONOR B. FELL



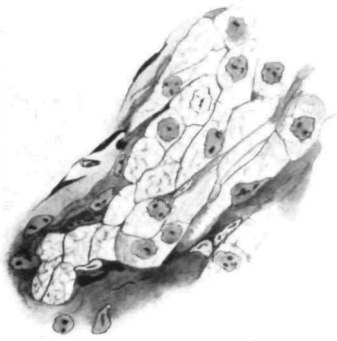8



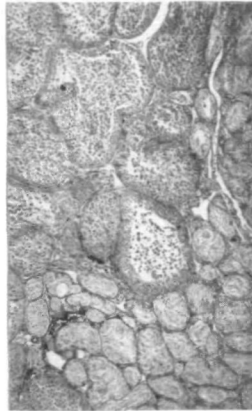
9



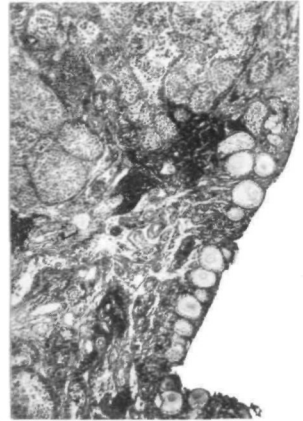
11



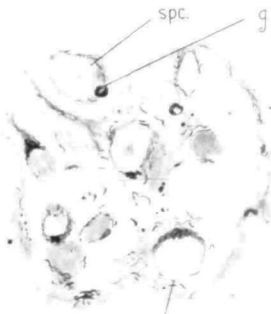
10



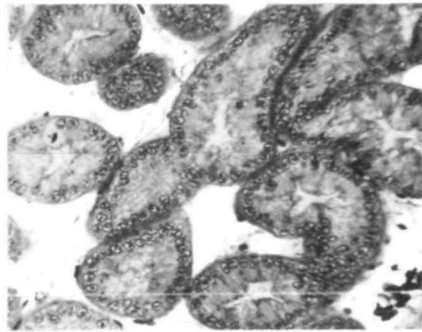
12



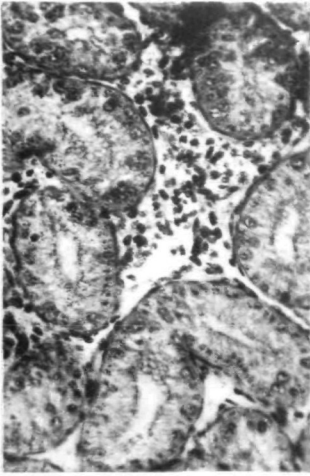
13



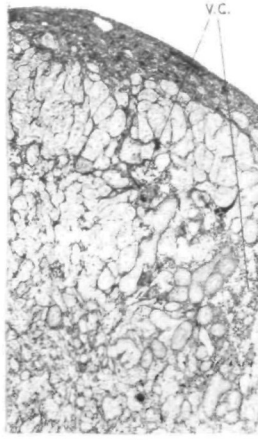
14



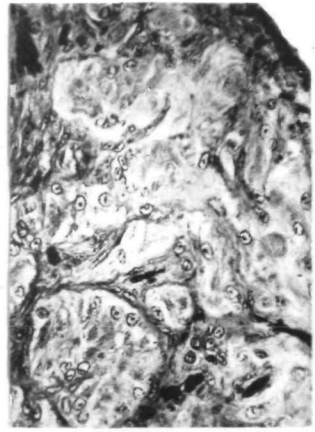
15



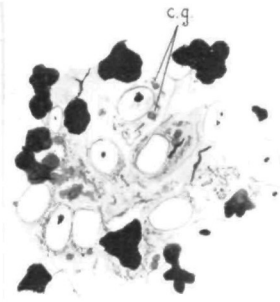
16



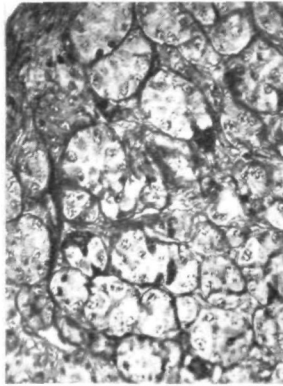
17



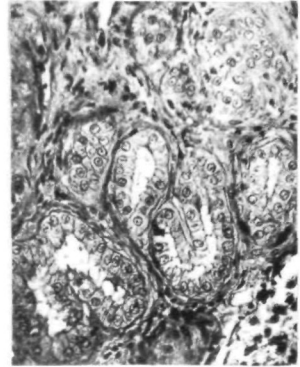
18



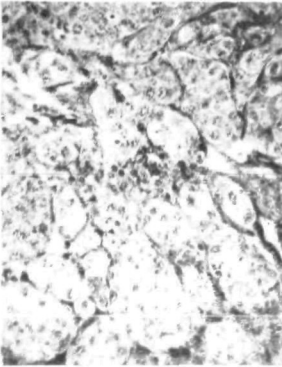
19




20



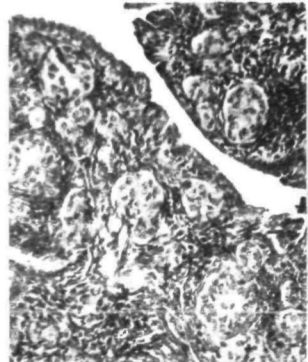
21



22



23



24