

Formation of feathers on chick foot scales: a stage-dependent morphogenetic response to retinoic acid

By DANIELLE DHOUILLY,¹ MARGARET H. HARDY²
AND PHILIPPE SENDEL¹

*From the Laboratoire de Zoologie et Biologie animale,
Equipe de recherche associée au CNRS n° 621, 'Morphogénèse
expérimentale', Université Scientifique et Médicale de Grenoble*

SUMMARY

In the chick embryo, large scales (*scuta*) form on days 9–11 on the anterior face of the shank and the upper surface of the toes; smaller scales (*scutella*) appear on day 11 on the posterior face of the shank; most of the smallest scales (*reticula*) form on days 12 and 13 on the plantar surface of the foot.

A single injection of 125 µg of retinoic acid (RA) into the amniotic cavity caused the formation of feathers on the foot scales in locations and percentages differing according to the age of embryos at the time of treatment. Injection at 10 days caused feathers to form on the feet in 57% of the embryos, almost all of which bore feathers on their scuta and scutella; a few reticula were occasionally affected. When treated at 11 days, 48% of embryos had feathered feet, the tarsometatarsal scutella and digital reticula being most frequently affected. Treatment at 12 days resulted in feathers on the feet of 15% of the embryos, all of which bore feathers on the reticula only, while the scuta and scutella were not affected.

It was concluded that the foot skin regions which were affected by RA treatment were those in which scale morphogenesis was starting or about to start at the time of injection. These regions contained pre-placodal or placodal stages of scuta and scutella, and the pre-elevation or elevation stages of reticula.

INTRODUCTION

It has been known for many years, from the pioneering work of Fell and Mellanby in 1953, and from many other reports (Fell, 1957; McLoughlin, 1961; Rothberg, 1967; Beckingham-Smith, 1973; Peck, Elias & Wetzel, 1977), that retinoids (vitamin A and derivatives) produce a mucous metaplasia in embryonic tarsometatarsal chick epidermis, and inhibit keratinization. In mammals, it has been found that retinoids not only act at the cellular level by transforming keratinocytes into mucus-secreting cells (Lawrence & Bern, 1963; New, 1965; Plewig, Wolff & Braun-Falco, 1971; Wong, 1975), but that in at

¹ *Authors' address:* Laboratoire de Zoologie et Biologie animale, Université Scientifique et Médicale de Grenoble, B.P. 53, 38041 Grenoble, France.

² *Permanent address:* Department of Biomedical Sciences, University of Guelph, Guelph, Ontario, Canada N1G 2W2.

least one developing tissue they are also able to elicit a morphogenetic response, namely the transformation of whisker follicles into skin glands, as shown by Hardy in 1968. Vitamin A was first applied to avian and mammalian skin in the form of retinol or retinyl acetate. More recently, it has become evident that retinoic acid (RA) is a more potent molecule than the above for many of the reported actions on mammalian and avian skin (Fulton, 1975; Peck *et al.* 1977).

All the transformations at the cellular level effected by retinoids seem to be basically reversible events, and they require the continued presence of the retinoids for their maintenance (Fell & Rinaldini, 1965). We report here another type of response of chick embryo tarsometatarsal skin to retinoic acid. This is a morphogenetic response, which was obtained *in ovo* and, like the whisker follicle transformation (Hardy & Bellows, 1978), it resulted in a permanent change in cutaneous appendages, namely the formation of feathers on the chick foot scales.

In a preliminary study (Dhouailly & Hardy, 1978), this experimental ptilopody was obtained in 85% of embryos which had received three injections of 125 μg of RA at 10, 11 and 12 days. In this case of repeated treatments, the number and distribution of feathers on the feet were highly variable and the data were difficult to analyse.

More recently we found that a *single* dose of RA was sufficient to elicit feather formation and that a strict correspondence could be established between the time sequence of appearance of scales (Sawyer, 1972; Sawyer & Craig, 1977) and their sensitivity to the retinoid.

MATERIALS AND METHODS

The chick embryos were from F_2 crosses of Wyandotte \times Rhode Island Red breeds. Eggs were incubated at 38 °C and windows in the shell were prepared at 3 days of incubation.

Retinoic acid (*all-trans* retinoic acid, Sigma) was dissolved in absolute ethanol, and administered as single or repeated injections (0.05 ml) into the amniotic cavity. Nine-day embryos received a relatively small (31.2 μg) single dose, as higher doses killed 100% of them within 24 h. Ten-, 11- and 12-day embryos received a single dose of 125 μg . Our preliminary experiments (Dhouailly & Hardy, 1978) had shown that, at these stages, 125 μg was the most suitable dose to obtain an exploitable percentage of both surviving embryos and morphogenetic aberrations. Embryos with repeated treatment either received 125 μg of RA at 10 and 11 days (i.e. a cumulative dose of 250 μg), or were injected with three doses of either 62.5 or 125 μg at days 12, 13 and 14 (i.e. a cumulative dose of 187.5 or 375 μg). Control embryos were injected at corresponding times with 0.05 ml of absolute ethanol alone.

Most of the surviving embryos were recovered at 17 days of incubation and fixed in Bouin-Hollande's fluid. A few others were sacrificed at hatching.

For precise determination of early developmental stages of scale primordia which were present at the time of injection, the entire skin from anterior and posterior surfaces of feet of 9- to 14-day chick embryos was dissected away from the underlying tissues, fixed in 2% glutaraldehyde, post-fixed in 1% osmium tetroxide, then dehydrated, embedded in Epon, and observed in transmitted and reflected light with a stereomicroscope. This technique allowed a precise observation of the earliest epidermal thickening during placode formation in scale rudiments, which appeared as opaque patches in an otherwise translucent skin.

RESULTS

I. *Distribution and sequential appearance of chick scales*

Three types of scales are distinguished on the feet of chickens (Lucas & Stettenheim, 1972). Large, distally overlapping scales (*scuta*) are arranged in two longitudinal rows (*ca.* 2×18 scales) on the anterior face of the shank (tarsometatarsus) and one row on the upper face of each toe (*ca.* 7, 15, 20 and 18 scales on toes I, II, III and IV respectively) (Figs. 1 and 2). Smaller, proximally overlapping scales (*scutella*) are arranged in two longitudinal rows (*ca.* 11 and 14 scales) on the posterior face of the shank (Fig. 3). The number of *scuta* and *scutella* is variable and cannot be determined with accuracy, because they may be split longitudinally and they gradually decrease in size towards the proximal (and, in the case of *scutella*, also the distal) end of the scale field, where the latter merges indistinctly with areas occupied by smaller scales. These small scales, called *reticula*, are non-overlapping and cover the remainder of the surface of the foot (Fig. 3). Furthermore, it appears appropriate to distinguish, among the *reticula*, larger ones which we propose to call *marginal reticula* and which are located in two or three rows along the lateral aspect, and in three to six rows along the medial aspect of the shank, between the *scuta* and *scutella*, and in one to three rows on the medial and lateral aspects of the digits, between the *scuta* and the small *reticula* which cover the digital pads and inter-pad spaces.

The primordia of *scuta* and *scutella* (epidermal placodes) and those of *reticula* (slight skin elevations) appear in a strict temporal sequence, as described by Sawyer (1972) and Sawyer & Craig (1977) and illustrated in detail from our specimens in Fig. 1.

II. *Control embryos*

(1) *Uninjected control embryos*

A slight manifestation of ptilopody (feathers on the feet) may occasionally occur in breeds of fowl characterized by feet without feathers, such as the Wyandotte and Rhode Island Red breeds. Out of 90 non-treated 17-day embryos, one of them (1.1%) presented one feather on each of two *scuta* of the

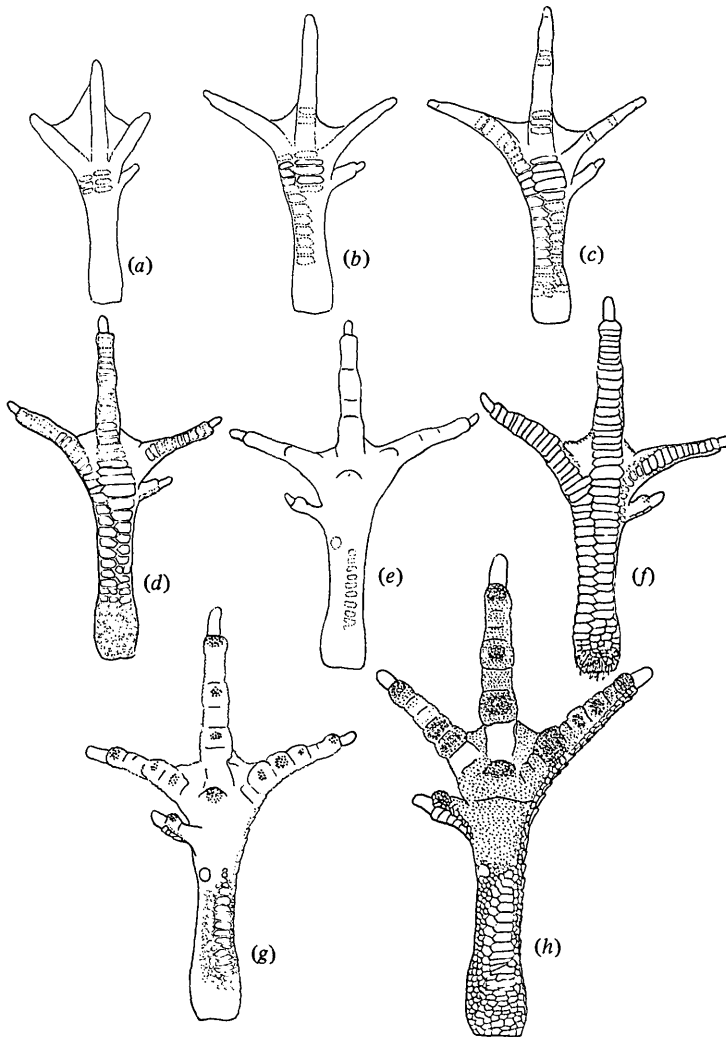


Fig. 1. Schematic drawings of the left foot of 9- to 14-day chick embryos. Placode stages of scutum and scutellum morphogenesis are indicated by dotted lines.

(a) At 9 days, formation of a first group of 6 scuta on the anterior surface of the metatarsal region.

(b) At 10 days, formation of the first row of scuta on the anterior face of the tarsometatarsus.

(c) At 10.5 days, formation of the second row of tarsometatarsal scuta and of the first scuta on the upper face of digits.

(d) and (e) At 11 days, formation of last digital scuta on the upper face of digits (d) and formation of spur and scutella on the posterior face of the tarsometatarsus (e).

(f) and (g) At 12 days, formation of the last scuta at the base of the second digit on the upper face (f) and of the first groups of reticula on the metatarsal and digital pads of the plantar face (g) and of some marginal reticula.

(h) At 14 days, except for the base of digits II and III on the plantar face, all the foot integument is covered by scales.

lateral row of the left shank, and one feather on each of three scuta of the corresponding row of the right shank.

(2) *Ethanol-treated embryos*

Sixty-five embryos, ranging from 9 to 14 days, received from one to three intra-amniotic injections of 0.05 ml of absolute ethanol. Thirty-eight (58 %) survived to 17 days and were normal, particularly with respect to foot integument. No case of even slight ptilopody was observed (Figs. 2 and 3). One embryo had abnormally short claws.

III. *Effects of retinoic acid on chick embryos*

Four types of external anomalies were observed in the 17-day embryos surviving after RA injection (Table 1). Three of them were malformations of beak, feathers and toes and one was characterized by the formation of normally shaped cutaneous appendages in an abnormal location, namely feathers on the foot scales (Figs. 4 and 5). The supernumerary feathers did not appear to inhibit or interfere with the normal appearance and pattern of scales. The resulting morphology was similar to that which is characteristic of certain breeds of fowl (Lucas & Stettenheim, 1972) and referred to as *ptilopody*. Two of the anomalies were obtained with a relatively high frequency: malformed feathers within the feather tracts (club-shaped feathers) and ptilopody. The frequency of the anomalies was dependent on the dose of RA, whereas their type and their distribution (in the case of malformed feathers and of feathered scales) were dependent, as reported below, on the age of embryos at the time of treatment.

Malformations of toes and beak occurred when RA was administered to embryos before 11 and 12 days of incubation respectively. Anomalies of toes consisted in acropodial truncature, resulting in shortening or absence of claws (Fig. 6), associated or not with the loss of the last phalanx. Malformed beaks were characterized either by a shortening of the lower jaw, associated with a downward curvature and twisting of the upper jaw, or by the downward curvature of both upper and lower jaws (Fig. 6). It should be noted that many embryos observed one day after RA treatment showed swollen and blood-filled feather buds, and a few showed also swelling of digit extremities, accompanied by blood stasis.

Malformed feather filaments were obtained after RA treatment at 10, 11 or 12 days of incubation. They were club-shaped, with a proximal peduncle of normal diameter but variable length, and an apex which was dilated into a spherical shape. The distribution of these abnormal feathers within the different tracts varied with the age at treatment: in embryos treated at 10 days, the most frequently affected tracts were the spinal and femoral ones, and more specifically the earliest feathers in these tracts (Fig. 6). In embryos treated at 11 days,

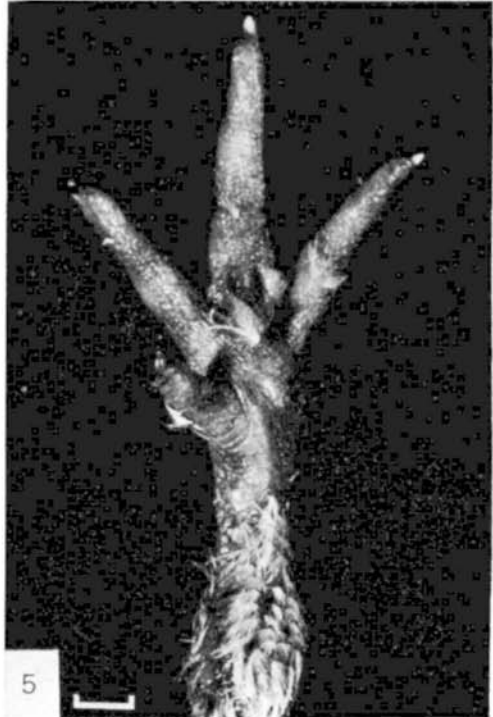
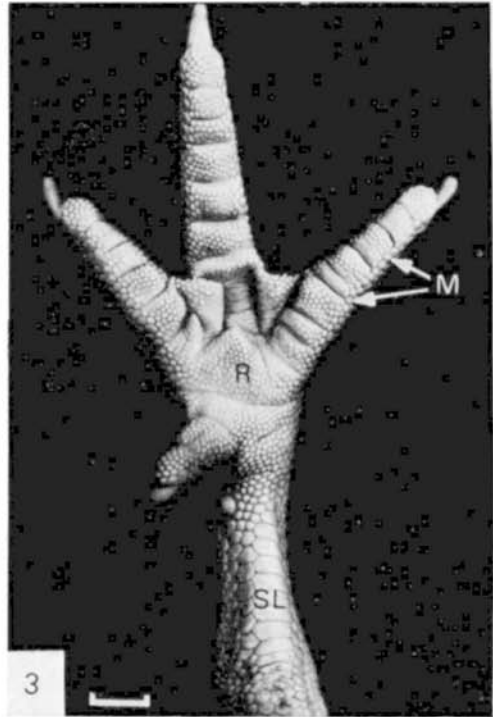



Table 1. *Effects of retinoic acid on chick embryos*

Age at injection (days)	Dose (μg)	Number of injected embryos	Number and (percentage) of embryos recovered at 17 days	Number and (percentage)* of embryos with:			
				Malformed beak	Acropodial truncature	Club-shaped feathers	Feathered feet
9	31.2	46	10 (22%)	0	1 (10%)	0	1 (10%)
10	125	158	44 (28%)	4 (9%)	6 (14%)	21 (48%)	25 (57%)
11	125	114	58 (51%)	1 (2%)	0	32 (55%)	28 (48%)
12	125	105	47 (45%)	0	0	15 (32%)	7 (15%)
10 and 11	2 \times 125	164	41 (25%)	9 (22%)	10 (24%)	38 (93%)	34 (83%)
12, 13 and 14	3 \times 62.5	37	28 (76%)	0	0	17 (61%)	3 (11%)
	1 \times 125	46	21 (46%)	0	0	13 (62%)	1 (5%)

* With respect to recovered embryos.

ventral, alar and capital tracts were preferentially affected (Fig. 7). After treatment at 12 days, most embryos presented club-shaped feathers around the eyes.

Retinoic acid-induced ptilopody occurred in 57% of embryos treated at 10 days, in 48% of embryos treated at 11 days and in 83% of embryos treated successively at 10 and 11 days. When RA was administered to 12-day embryos or repeatedly at 12, 13 and 14 days, only a small percentage (5–15) presented feathered feet. The distribution of feathers on scales, which was strongly dependent on the age of embryos at the time of treatment, is analysed in detail in the following section.

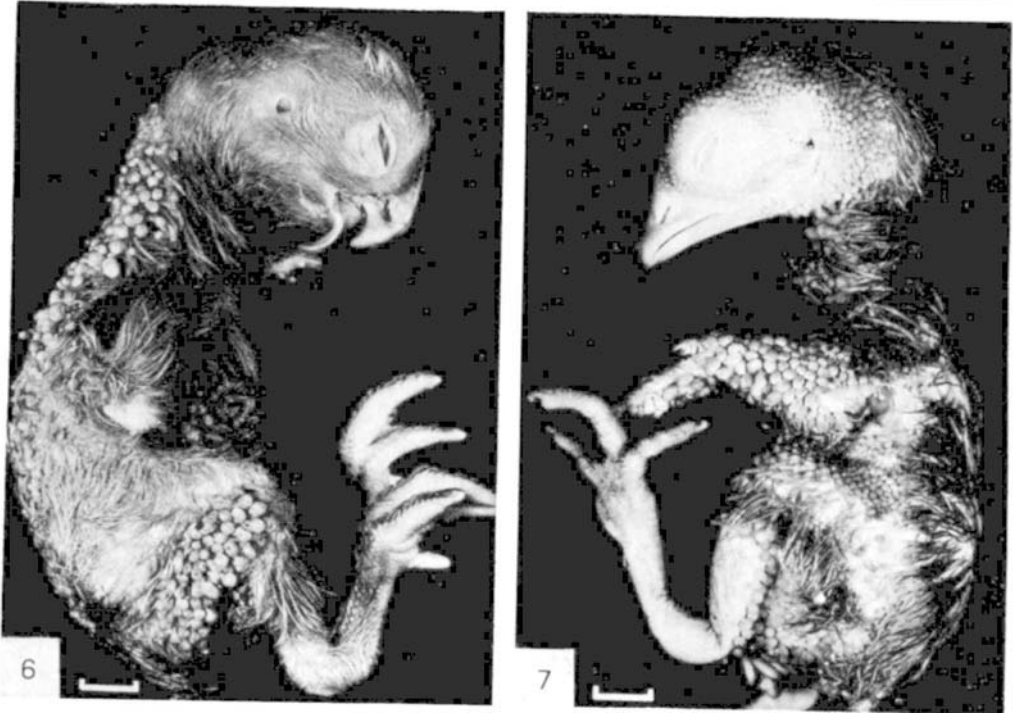IV. *Retinoic acid-induced ptilopody*

In contrast with those of the regular feather tracts, the majority of feather filaments formed on the scales were normally shaped (Figs. 8–11). In those embryos which were carried to hatching, these feather filaments gave rise to normal down feathers with barbs (16–26) and barbules.

FIGURES 2–5

Left feet of chickens treated twice, at 10 and 11 days of incubation, with ethanol (Figs 2 and 3) or with an ethanol solution of retinoic acid (Figs 4 and 5). After treatment with ethanol, 17-day embryo shows normal scale pattern and development on anterior face (Fig. 2) and posterior face (Fig. 3) of foot. After treatment with retinoic acid, hatched chicken shows burst down feathers on all scuta of anterior face (Fig. 4) and on all scutella and some reticula of posterior face (Fig. 5). S, scuta; SL, scutella; M, marginal reticula; R, reticula.

Figs 2 and 3, bar = 0.3 cm; Figs 4 and 5, bar = 0.4 cm.



Figs 6 and 7. Seventeen-day chick embryos, treated with a single dose of $125 \mu\text{g}$ of retinoic acid at 10 days (Fig. 6) or 11 days (Fig. 7). Note that almost all feathers which are malformed (club-shaped) in one embryo are normal in the other and *vice versa*.

Fig. 6. Treatment at 10 days results in feathers being affected in the mid-spinal tract, lower femoral tract and pectoral tract. Note also abnormal curvature of beak and truncated digits. Feet bear feathers on scuta and scutella (see further pictures for details).

Fig. 7. Treatment at 11 days causes malformation of feathers in capital tract (except peri-ocular tract), ventral cervical tract, alar tracts, upper femoral tract, crural tract and abdominal tract. (Note: most club-shaped feathers of left crural tract fell off at fixation of the embryo.) Feet bear feathers on reticula only. Bar = 0.6 cm.

As a rule, one or two feathers were borne by the distally oriented free edge of the affected scuta (Figs. 8 and 9). In a few cases, more than two feathers developed on each scutum, and were then more or less fused laterally (Fig. 12). The majority of the affected scutella bore only one feather (Fig. 13), but some formed two feathers, from their proximally oriented free edge. The affected reticula never formed more than one feather (Fig. 14). In most cases, the interscale furrows were normally developed and the distribution pattern of scales was normal. In a few embryos (2%), the reticula of the plantar face had not formed at 17 days and the skin was folded into irregular wrinkles.

The regional distribution of feathered scales on the feet of treated embryos showed a high degree of bilateral symmetry. This distribution was analysed in

detail by counting the number of feathers formed on the right foot of the embryos which had been treated with a single dose of RA at 9, 10, 11 or 12 days and of those which were treated repeatedly at 10 and 11 days or at 12, 13 and 14 days. It varied markedly with the age at which the embryos were treated (Table 2).

Only one embryo treated at *9 days* (31.2 µg) formed two feathers on each foot; they were located on the metatarsus, at the base of the fourth digit.

Embryos treated at *10 days* (Figs. 8, 9 and 12) developed numerous (up to 210) feathers on most (sometimes all) tarsometatarsal scuta, as well as on a variable number of scutella and of digital scuta. A small number (four) of these embryos (16%) also formed a few feathers on the marginal reticula, and from one to three feathers (Fig. 9, inset) in the central metatarsal pad. It was noted that, in three of these four embryos, a group of two to nine scuta at the junction between tarsometatarsus and digits III and IV were normal and did not bear any feathers (Fig. 9).

Embryos treated at *11 days* developed feathers on scuta in only 36% of cases, chiefly on the distal phalanges and at the base of digit II (Fig. 10). The tarsometatarsal scuta were unaffected or else bore only short feather filaments. In addition, these embryos formed up to 62 feathers on the marginal reticula, up to 50 on the scutella (Figs. 11 and 13), up to 70 on the digital pads (Fig. 11) and up to 35 feathers on the central metatarsal pad (Figs. 11 and 14).

When embryos received two successive injections of RA, at *10 and 11 days*, three different distribution patterns of feathered scales were observed in the 83% of chickens which were affected: either the pattern was similar to that of the embryos treated at 10 days (41%) or at 11 days (10%), or it displayed the features of both patterns simultaneously (32%) (Figs. 4 and 5).

Embryos treated at 12 days did not form any feathers on either scuta or scutella; but most if not all reticula formed feather buds (Fig. 15).

Embryos which received three successive injections at *12, 13 and 14 days* bore feathers on reticula only (Fig. 16), in the same location as in embryos which were treated with a single injection at 12 days.

DISCUSSION AND CONCLUSIONS

Some of the effects of retinoic acid on chick embryos could be related to its well-known influences on chondroitin sulphate metabolism (Kochhar, 1967) and on developing blood vessels (Fraser & Travill, 1978). Impaired chondroitin sulphate synthesis could explain beak malformations, which appear to result from interference with maxillary and mandibular growth. Damage to forming capillaries could lead to fluid imbalance, oedema and haemorrhage in the apical parts of feather filaments and of toes. The correspondence between the affected feather tracts and the age of embryos at the time of treatment shows that feathers are RA-sensitive only during a short period of their development,

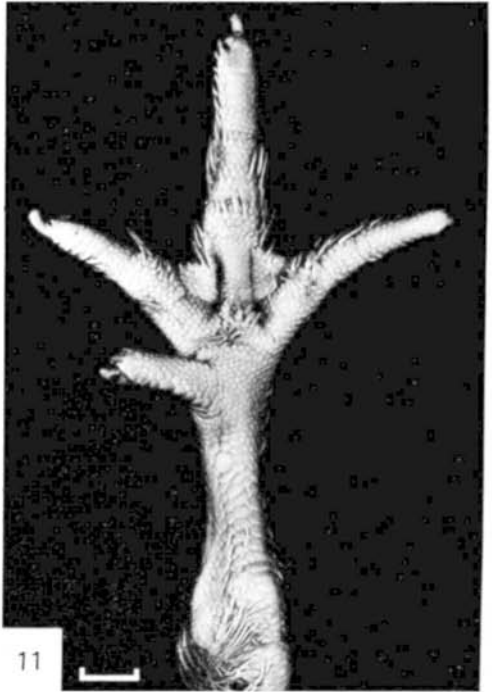

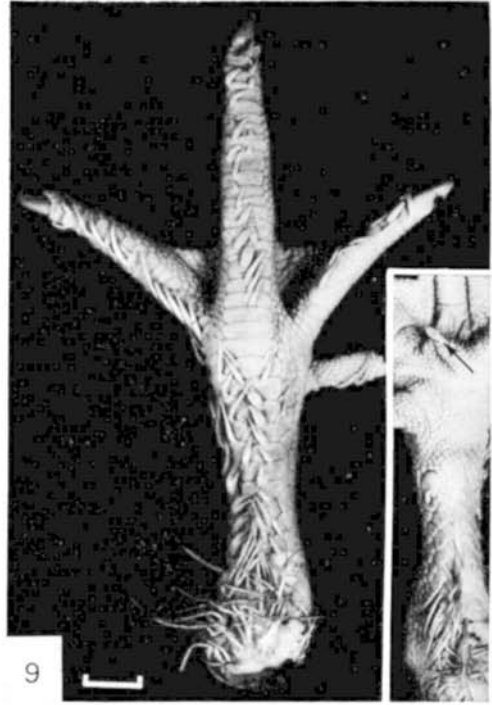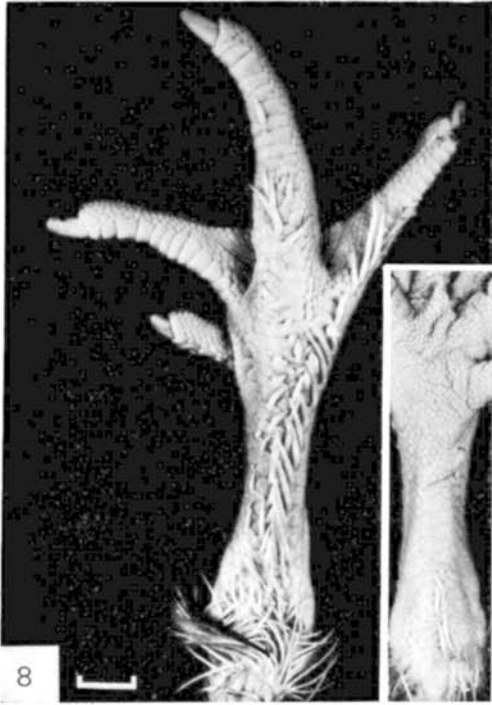


Table 2. Distribution of feathered scales on the feet of RA-treated embryos

Age at injection (days)	Number of embryos with feathered feet	Number and percentage of embryos with feathered scales in each of the following categories: (In parentheses, mean number of feathers per category per right foot \pm S.E.M.)*					
		36† tarsometatarsal scuta	60† digital scuta	25† tarsometatarsal scutella	200† marginal reticula	400† metatarsal reticula	700† digital reticula
10	25	25 100% (36 \pm 4)	20 80% (30 \pm 6)	23 92% (15 \pm 2)	4 16% (3 \pm 2)	4 16% (0.3 \pm 0.1)	0
11	28	10 36% (4 \pm 2)	10 36% (4 \pm 2)	23 82% (17 \pm 2)	15 54% (12 \pm 3)	7 25% (4 \pm 2)	22 79% (20 \pm 4)
12	7	0	0	0	7 100% (all)‡	7 100% (all)‡	7 100% (all)‡
10 and 11	34	33 97% (41 \pm 4)	32 94% (55 \pm 4)	34 100% (37 \pm 3)	28 82% (14 \pm 2)	22 65% (3 \pm 1)	13 38% (3 \pm 1)
12, 13 and 14	4	0	0	0	4 100% (all)‡	4 100% (all)‡	4 100% (all)‡

* Mean number of feathers was calculated by dividing the total number of feathers borne by the right feet by the number of embryos in column 2. S.E.M. = standard error of mean.

† Approximate number of scales per normal foot.

‡ In these cases, all or nearly all reticula bore short feathers; their precise absolute number was not determined.

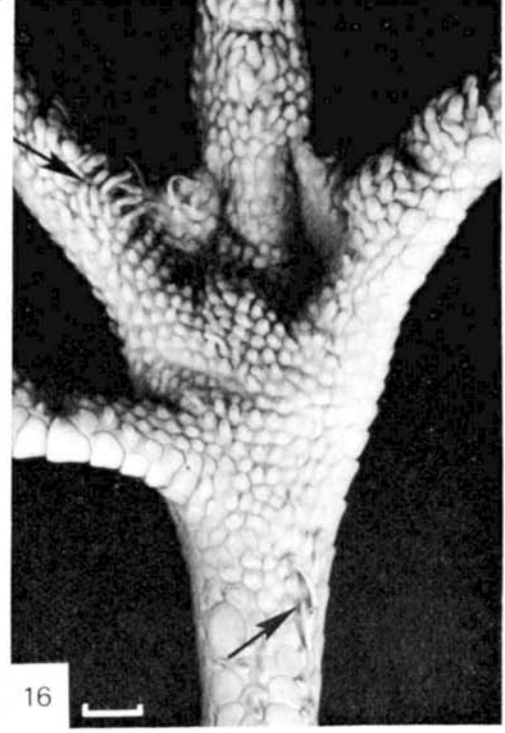
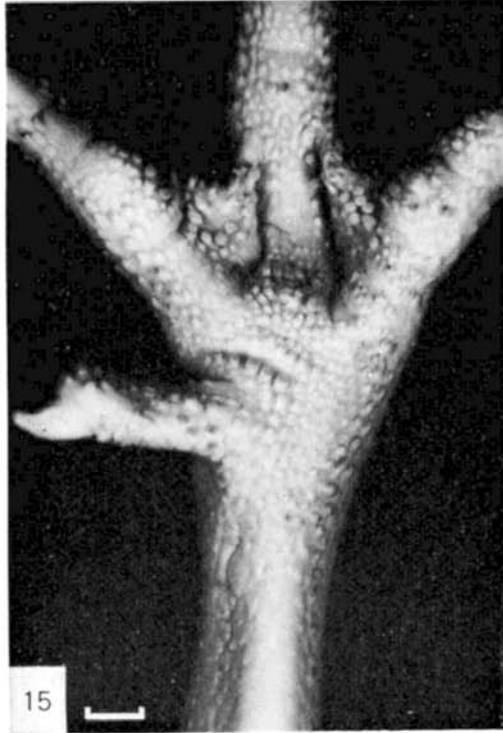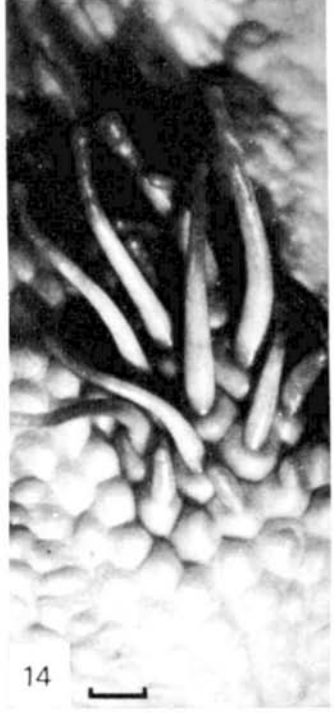
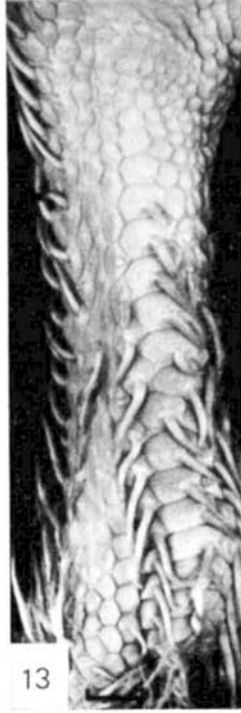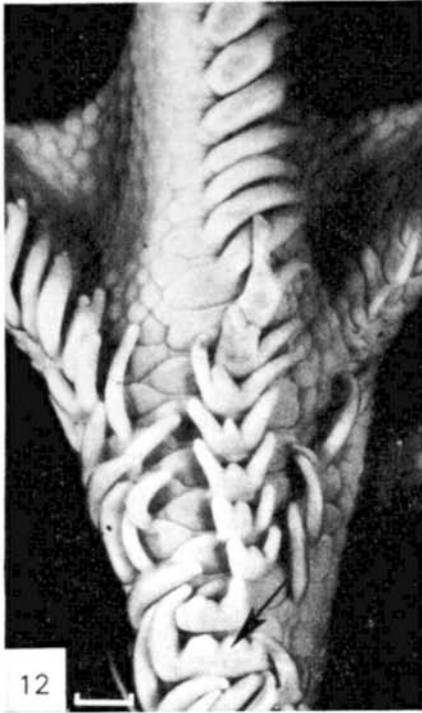FIGURES 8-11

Feet of 17-day chick embryos, treated by a single injection of retinoic acid. Compare the distribution of feathered scales and the time sequence of scale formation (Fig. 1).

Figs 8 and 9. Embryos treated at 10 days. In one case (Fig. 8), feathers are borne by tarsometatarsal scuta, by some digital scuta and by a few scutella (inset). In the other case (Fig. 9), almost all scuta bear feathers, except the first two scuta at the base of digit III and the last ones at the base of digit II; nearly all scutella, and the spur, bear feathers, as well as one reticulum in the middle of the metatarsal pad (arrow, inset).

Figs 10 and 11. Embryo treated at 11 days. On the anterior face (Fig. 10), feathers are borne by the distal scuta of digits II, III and IV and by scuta at the base of digit II. On the posterior face (Fig. 11), feathers are borne by scutella and by metatarsal and digital pad groups of reticula, as well as by marginal reticula.

Figs 8 and 9, bar = 0.25 cm. Figs 10 and 11, bar = 0.3 cm.



at the stage when vascularization of the feather bud is being established (buds of 0.3–0.5 mm in length).

In addition, retinoic acid induces the formation, on the foot scales, of normal feather filaments, which at hatching give rise to normal down feathers. Thus it is able to elicit an abnormal morphogenetic response from prospective scaled foot integument. The specific distribution pattern of feathered scales for each of the three stages at which RA was administered, considered together with the time-sequence of appearance of the scales, leads us to conclude that scale primordia are sensitive to RA only during a limited period of their development. No information can be derived from the result of 9-day injections: although one out of ten surviving embryos presented a few feathers on the earliest appearing scuta, this slight ptilopody cannot be distinguished from that which can occasionally occur without treatment (see Results, Section II). Single injections at 10 days were found to produce feathers constantly on scuta which appear as placodes at 10 (Fig. 1*b*) and 10.5 days (Fig. 1*c*) and inconstantly on those which form at 9 days (Fig. 1*a*) and 11 days (Fig. 1*d*), and on a variable number of scutella which appear as placodes at 11 days (Fig. 1*e*). Single injections at 11 days caused the formation of feathers on the scuta and scutella which appear at 11 days (Fig. 1*d* and *e*), on the last scuta, which form at 12 days at the base of the second digit (Fig. 1*f*) and on scutella and reticula which appear at 12 days (Fig. 1*g*), and only inconstantly on scuta already present at 10 days. Single injections at 12 days induced the formation of feathers on reticula which appear at 12 and 13 days.

Thus, it was found that a single injection affected only those scuta and scutella which became discernible as opaque placodes, or reticula which appeared as elevations, on the day of injection and the following day. The scales which were due to appear (as placodes or elevations) 48 h after the injection of RA were seldom affected. Likewise the scales which had started their morphogenesis

FIGURES 12–16

Distribution of feathers on the different types of scales after RA treatment in embryos fixed at 17 days.

Fig. 12. Embryo treated at 10 days. Formation of 1–4 feathers (fused laterally, arrow) on the distal free edge of each scutum.

Figs 13 and 14. Embryo treated at 11 days. Fig. 13. Formation of one feather on the proximal edge of each scutellum and on most of the marginal reticula. Fig. 14. A group of feathers (one per reticulum) on the metatarsal pad.

Fig. 15. Embryo treated at 12 days. Each reticulum of the posterior face is transformed into an elongated structure, similar to a feather bud.

Fig. 16. Embryo treated by repeated injections at 12, 13 and 14 days. Note, by comparison with Fig. 15, that the multiple treatment led to the formation of a number of feather filaments (*arrow*) in addition to the elevated bud-like structure borne by each reticulum. Spur, scuta and scutella are not affected.

Fig. 12, bar = 0.8 mm. Fig. 13, bar = 0.9 mm. Fig. 14, bar = 0.4 mm. Figs 15 and 16, bar = 1.3 mm.

24 h or more before the injection, and had thus attained the asymmetrical placode stage at the time of injection, were rarely affected, while those that had attained the hump stage were never affected.

It is not known for how long after administration the retinoic acid molecule remains biologically active in the tissues of the chick embryo. Injections at 10 days affect tarsometatarsal and digital scuta which arise as placodes at 10 and 11 days, but do not affect the scuta at the base of digit II (which appear at 12 days), only rarely (16%) affect a few marginal reticula and central metatarsal reticula, and never affect any of the other 12-day reticula (such as those of the digital pads). These results can be interpreted in different ways according to whether RA remains active for less than 24 h or for more than 24 h. If RA is degraded within 24 h it follows that the pre-placodal (or pre-elevation) stage, as well as the placodal (or elevation) stage must be sensitive to the retinoid. If, however, RA persists in the tissues for more than 24 h, it is possible that only the placodal (or elevation) stage of each scale is the sensitive one. Results obtained by De Luca & Zile (1975) on the persistence of injected RA in rats show that RA is degraded in these animals within 48 h. If the chick embryo does not degrade RA any faster than the adult rat, the second of the above possibilities is favoured. In the present state of our knowledge, we can best interpret the findings by the following hypothesis: RA, reaching the skin within hours of injection, acts on those scales which are at the placode (or elevation) stage of development, and possibly acts also on some scales at a slightly earlier and a slightly later stage. It is degraded after 48 h or less, and perhaps after less than 24 h.

Two injections of 125 μg of RA, at 10 and 11 days, resulted in perturbation of foot cutaneous appendages which could be classified into three categories: (1) some surviving embryos had a distribution pattern of feathered scales similar to that of embryos treated at 10 days; (2) some had a distribution resembling that of embryos treated at 11 days; (3) some displayed the features of both distribution patterns simultaneously, and some had normally scaled feet. This variability may be easily interpreted if one considers the results of the 10-day and 11-day series, each of which yielded a certain proportion of feathered feet (0.57 and 0.48, respectively) and of normal feet (0.43 and 0.52, respectively). The combination of these proportions leads to the following 'theoretical' percentages of double-treated embryos: 30% (0.57×0.52) should display the 10-day phenotype; 21% (0.43×0.48) should display the 11-day phenotype; 27% (0.57×0.48) should show both phenotypes simultaneously; and 22% (0.43×0.52) should be non-affected. As these calculated percentages are not significantly different from the observed ones (41, 10, 32 and 17%, respectively), it is reasonable to entertain the hypothesis that two successive injections of RA have additive effects on the foot integument. In addition, the results obtained with triple injections at 10, 11 and 12 days (Dhouailly & Hardy, 1978) can be interpreted and understood in a similar manner.

In conclusion, RA is able to elicit the formation of feathers on the scaled foot integument of the chick embryo. The mechanism of action of the retinoid is as yet unknown. It is clear, however, in view of the existence of domestic breeds of fowl with feathered feet (genetic ptilopody), that RA somehow interferes with scale morphogenesis and thereby reveals a latent ability of avian foot integument to produce feathers. Apparently the formation of scales requires additional and possibly inhibitory region-specific information on top of the trivial and 'ubiquitous feather message' (Dhouailly, 1978). Retinoic acid, by weakening the scale message, would leave the feather message free to be expressed.

The collaboration was made possible by a travel grant from the National Research Council of Canada to Margaret H. Hardy, who was on sabbatical leave from the University of Guelph when the work was undertaken. An operating grant from the National Research Council helped to defray the expenses; it was continued in 1979 by financial help from INSERM (Contrat de recherche libre n° 7915142). The authors are grateful to Mrs N. Cambonie, Mrs Y. Bouvat and Mrs J. Lana for their technical assistance.

REFERENCES

- BECKINGHAM-SMITH, K. (1973). Early effects of vitamin A on protein synthesis in the epidermis of embryonic chick skin cultured in serum-containing medium. *Devl Biol.* **30**, 241-248.
- DE LUCA, H. F. & ZILE, M. (1975). Aspects of teratology of vitamin A acid (β -all-trans retinoic acid). *Acta derm.-vener., Stockh.* Suppl. 74, International Symposium, pp. 13-20.
- DHOUAILLY, D. (1978). Feather-forming capacities of the avian extra-embryonic somatopleure. *J. Embryol. exp. Morph.* **43**, 279-287.
- DHOUAILLY, D. & HARDY, M. H. (1978). Retinoic acid causes the development of feathers in the scale-forming integument of the chick embryo. *Wilhelm Roux' Arch. devl Biol.* **185**, 195-200.
- FELL, H. B. (1957). The effect of excess vitamin A on cultures of embryonic chicken skin explanted at different stages of differentiation. *Proc. R. Soc. B*, **146**, 242-256.
- FELL, H. B. & MELLANBY, E. (1953). Metaplasia produced in cultures of chick ectoderm by high vitamin A. *J. Physiol., Lond.* **119**, 470-488.
- FELL, H. B. & RINALDINI, L. M. (1965). The effects of vitamin A and C on cells and tissues in culture. In *Cells and Tissues in Culture*, vol. 1 (ed. E. N. Willmer), pp. 659-699. New York: Academic Press.
- FRASER, B. A. & TRAVILL, A. A. (1978). The relation of aberrant vasculogenesis to skeletal malformation in the hamster fetus. *Anat. Embryol.* **154**, 111-120.
- FULTON, J. E. (1975). Vitamin A acid - The last five years. *J. Cutaneous Pathol.* **2**, 155-160.
- HARDY, M. H. (1968). Glandular metaplasia of hair follicles and other responses to vitamin A excess in cultures of rodent skin. *J. Embryol. exp. Morph.* **19**, 157-180.
- HARDY, M. H. & BELLOWS, C. G. (1978). The stability of vitamin A-induced metaplasia of mouse vibrissa follicles in vitro. *J. invest. Derm.* **71**, 236-241.
- KOCHHAR, D. M. (1967). Teratogenic activity of retinoic acid. *Acta path. microbiol. scand.* **70**, 398-404.
- LAWRENCE, D. J. & BERN, H. A. (1963). Vitamin A and mucous metaplasia. *Ann. N.Y. Acad. Sci.* **106**, 646-653.
- LUCAS, A. M. & STETTENHEIM, P. R. (1972). *Avian Anatomy, Integument*, Part I and Part II. Agriculture Handbook 362. Washington: Agricultural Research Service. U.S. Department of Agriculture.

- McLOUGHLIN, C. B. (1961). The importance of mesenchymal factors in the differentiation of chick epidermis. I. The differentiation in culture of the isolated epidermis of the embryonic chick and its response to excess vitamin A. *J. Embryol. exp. Morph.* **9**, 370–384.
- NEW, D. A. T. (1965). Effects of excess vitamin A on cultures of skin from the tail and pads of the embryonic rat, and from the trunk, tail and pads of the embryonic rabbit. *Expl Cell Res.* **39**, 178–183.
- PECK, G. L., ELIAS, P. M. & WETZEL, B. (1977). Influence of vitamin A on differentiating epithelia. In *Biochemistry of Cutaneous Epidermal Differentiation* (ed. M. Seiji and I. A. Bernstein), pp. 110–126. Baltimore: University Park Press.
- PLEWIG, G., WOLFF, H. H. & BRAUN-FALCO, O. (1971). Lokalbehandlung normaler und pathologischer menschlicher Haut mit vitamin A-Säure. *Arch. klin. exp. Derm.* **239**, 390–413.
- ROTHBERG, S. (1967). The cultivation of embryonic chicken skin in a chemically defined medium, and the response of the epidermis to excess of vitamin A. *J. invest. Derm.* **49**, 35–38.
- SAWYER, R. H. (1972). Avian scale development. I. Histogenesis and morphogenesis of the epidermis and dermis during formation of the scale ridge. *J. exp. Zool.* **181**, 365–384.
- SAWYER, R. H. & CRAIG, K. F. (1977). Avian scale development. Absence of an 'epidermal placode' in reticulate scale morphogenesis. *J. Morph.* **154**, 83–94.
- WONG, Y. C. (1975). Mucous metaplasia of the hamster cheek pouch epithelium under hypervitaminosis A. *Expl molec. Pathol.* **23**, 132–143.

(Received 12 October 1979, revised 1 February 1980)